

Full Length Research Paper

Anthelmintic activity of the white wormwood, *Artemisia herba-alba* against *Heterakis gallinarum* infecting turkey poults

Shaker A. Seddiek¹, Mohamed M. Ali², Hanem F. Khater^{3*} and Mohamed M. El-Shorbagy⁴

¹Avian Diseases Department, Animal Health Research Institute, Benha Branch, Benha 13111, Egypt.

²Biochemical and Nutritional Deficiency Diseases Department, Animal Health Research Institute, Benha Branch, Benha 13111, Egypt.

³Department of Parasitology, Faculty of Veterinary Medicine, Benha University, Moshtohor 13736, Egypt.

⁴Poultry Diseases Department, Faculty of Veterinary Medicine, Benha University, Moshtohor 13736, Egypt.

Accepted 3 May, 2011

Artemisia herba-alba is widely used in the Egyptian folk medicine as vermifuge. The objective of this study was to evaluate the proclaimed anthelmintic efficacy of crude aqueous extracts of *A. herba-alba*, ACEA, in comparison to albendazole, ABZ, against *Heterakis gallinarum* infecting turkey poults. 60, 1 day old large white turkey poults (males) were divided into four groups. Group 1 was neither infested nor treated. Groups 2, 3 and 4 were inoculated with 500 embryonated eggs of *H. gallinarum* at 1 day old. On day 25 post infestation and for three successive days, group 3 was treated with ABZ, 2.5% (20 mg/kg B. wt.) and group 4 was treated with ACEA (0.4 g/kg B. wt.) in drinking water. The whole experiment had been repeated three times. Seven days post treatments, ABZ and ACEA reduce egg output (97.31 and 97.78%, respectively), and worm burden of *H. gallinarum* (95.08 and 96.07%, respectively). The weight and feed conversion ratios were improved in group 4. Biochemical analysis and histopathological sections revealed the adverse effect of ABZ. ACEA is then considered as a good anthelmintic alternative therapy and recommended in the control of ascaridosis in poultry industry, since it is effective, safe, available and cheap.

Key words: *Heterakis*, herbal remedies, *Artemisia*, albendazole, turkey.

INTRODUCTION

Helminthiasis is frequent among Egyptian birds (Khater, 1993). Infection with intestinal roundworms have been estimated to cause production losses in the range of 10 to 20% due to impaired feed conversion, reduced growth and egg production, and increased mortality (Ikeme, 1971; Soulsby, 1982; Choudury and Das, 1993; Seddiek et al., 2007). The nematode *Heterakis gallinarum* (Movsessian and Pkhrikian, 1994) (family: Ascarididae) is cosmopolitan in domestic chickens and related birds. The worm (1 to 2 cm in length) lives in the cecum, where they feed on its contents. *H. gallinarum* is one of the most important nematodes of poultry due to its role in the epidemiology of histomoniasis (blackhead disease)

caused by a flagellate protozoan, *Histomonas meleagridis*, causing a particularly serious disease in turkeys (Papini and Cacciuttoli, 2008). *H. gallinarum* infections linked to histomoniasis have been well documented in chicken (Homer and Butcher, 1991; Permin, 2003). Blackhead disease causes high mortality in turkeys, sometimes approaching 100% of a flock. In chicken, the mortality may be 10 to 20% with high morbidity, although many outbreaks pass unnoticed (McDougald, 2005).

The life cycle of *H. gallinarum* is simple and direct, similar to that of *Ascaridia galli* with a minimum prepatent period of 22 days under temperate climatic conditions (Lund and Chute, 1972; Movsessian and Pkhrikian, 1994). After ingestion of the infective eggs and hatching of eggs in the upper small intestine, the larvae reached the caeca at the end of 24 h post-infestation (PI). The larvae are embedded in the mucosal layer of the caeca

*Corresponding author. E-mail: hafkhater@yahoo.com. Tel: +2013 2461 411. Fax: +2013 2460 640.

for a varying period of 3 to 12 days (Lund and Chute, 1972), and then the mature worms infest the lumen of blind caeca. Fertilization occurred and oviposition starts 22 to 25 days PI (Movsessian and Pkhrikian, 1994). Eggs of *H. gallinarum* contain a zygote when laid. They develop into the infective stage in 12 to 14 days at 22°C and can remain infective for four years in soil. Birds allowed to roam a barnyard usually are infected (Jansson et al., 2004; Roberts and Janovy, 2005).

If eaten by an earthworm, a juvenile may hatch and become dormant in the worm's tissues, remaining infective for at least a year. Since these nematodes do not develop further until eaten by a bird, an earth worm is a paratenic host (Roberts and Janovy, 2005). Diagnosis of *H. gallinarum* is based on faecal isolation of eggs or direct identification of adult worms in the intestine (Soulsby, 1982; Roberts and Janovy, 2005). *H. gallinarum* caused severe caecal alterations in the turkey poult characterized by necrosis, chronic typhlitis, haemosidrosis and nodular formation in the caeca (Menezes et al., 2003; Brener et al., 2006). The increasing prevalence of anthelmintic resistant strains of helminths (Walter and Prichard, 1985; Kaplan, 2004; Hoque et al., 2003; Borgsteede et al., 2007; Beech et al., 2011), drug residues in animal products (Kaemmerer and Butenkotter, 1973; McKellar, 1997), and high cost of conventional anthelmintics have created an interest in studying medicinal plants as an alternative source of anthelmintics. The use of plant extracts as mendicants may alleviate these obstacles. An additional constraint in anthelmintic use comes from the consumer and the ever-increasing need for the drug-free production of foods (Harper and Makatouni, 2002) as they are not only natural products but may comprise new therapeutic molecules to which resistance has not yet developed.

Medicinal plants have been used as a source of remedies since ancient times. The ancient Egyptians were familiar with many medicinal herbs and were aware of their usefulness in treatment of various diseases. When the Arabs came to Egypt, Arabic medicine was practiced and the "art" of healing made use of all available knowledge gained from different civilizations such as the Persian, Chinese, Greek, as well as the Ancient Egyptian.

It could create an herbal remedy export market and thereby create more jobs in the country. Egypt possesses an enormous diversity of plant resources, that is used for herbal remedies for humans and animals (Hifnawy et al., 2001; Khater, 2003; Shalaby and Khater, 2005; El Garhy and Mahmoud, 2007; Khater and Shalaby, 2008; Mobarak et al., 2008; Khater and Khater, 2009; Khater et al., 2009, 2011). Many *Artemisia* spp. (family: Asteraceae, formerly Compositae) have a prominent position in the herbal de-worming literature (El Garhy and Mahmoud, 2002; Iqbal et al., 2004; Caner et al., 2008; Urban et al., 2008; Tariq et al., 2009; Bashtar et al., 2011).

They also have a high value in several fields, as food plants (Benmansur et al., 1990; Fenardji et al., 1994; Benmansour and Taleb-Bendiab, 1998), anticoccidial (Naidoo et al., 2008; del Cacho et al., 2010), and antimalaria (World Health Organization, 2005; Ene et al., 2009) in medicine. The Romans used dried, unexpanded flower heads obtained from several species of the genus *Artemisia* in the first century, for the treatment of *Ascaris*, *Enterobius* and tapeworm infections and it became an important member of the European pharmacopoeia until the early 20th century (Mohamed et al., 2010).

The Anthelmintic effect of *Artemisia* species is caused by the sesquiterpene lactone, santonin (Rachkovskaia, 1978; Akhtar et al., 1982). *Artemisia herba-alba*, known as desert or white wormwood, known in Arabic as shih and in French as Armoise Blanche, is widely distributed in North Africa. It is used traditionally by the Egyptians as a vermifuge in addition to its other medical and veterinary uses (Saleh et al., 2006; Seddiek et al., 2007; Mobarak et al., 2008; Mohamed et al., 2010).

It has been used in folk medicine by many cultures since ancient times, used in Moroccan folk medicine to treat arterial hypertension and/or diabetes (Ziyyat et al., 1997; Tahraoui et al., 2007; Zeggwagh et al., 2008). During an ethnopharmacological survey carried out among the Bedouins of the Negev desert, it was found that *A. herba-alba* relieved stomach disorders (Friedman et al., 1986). In addition to the previous benefits *A. herba-alba* induced hypoglycemic effect (Al-Waili, 1988; Marriif et al., 1995). Moreover, the aqueous extract and essential oil of *A. herba-alba* expressed antileishmanial activity against *Leishmania major* (Hatimi et al., 2001). Herbal tea from this species has been used as antibacterial, analgesic, antispasmodic and hemostatic agents (Laid et al., 2008). The plant is used to bandage wounds, cure stomach-ache, and neuralgia and other pain when mixed with henna and diluted in water and applied to the head (Le Floch, 1983). Alternative treatments for gastrointestinal helminths in poultry (for example anthelmintic plants) have been investigated in several studies (Mali et al., 2007; Brito et al., 2009; Kosalge and Fursule, 2009; Parida et al., 2010).

However, scientifically validated data on the efficacy of herbal treatments against *H. gallinarum* remain scarce and mainly *in vitro* (Nagaich, 2000). As the people consume *A. herba-alba* to cure helminthic infections as per the literature, we attempted to investigate this medicinal plant for its claimed anthelmintic activity. The present study was designed to investigate the efficacy of treatments with aqueous cured extract of *A. herba-alba* (ACEA) and albendazole (ABZ), as a reference anthelmintic, on turkey poult experimentally infected with *H. gallinarum* eggs.

Therefore, several parameters have been evaluated such as fecal egg count reduction (FECR), worm count reduction (WCR), growth performance (body weight, body gain and food conversion ratio, FCR), biochemical,

and histopathological features.

MATERIALS AND METHODS

Parasite

H. gallinarum adults were obtained from the caeca (blind portion) of the freshly killed turkey poults (naturally infested) and washed several times in saline. Heterakid ova were obtained by gentle crushing of gravid female worms, with a small spatula, through a 150 µm sieve into small Petri dishes containing distilled water (2 to 3 mm in depth). Few drops of 2% formalin solution had been added to each Petri dish, and then incubated for 21 to 28 days at $28 \pm 2^\circ\text{C}$ to permit embryonation of the eggs (Oliver, 1953).

Experimental design

To study the effect of *A. herba-alba* on *H. gallinarum* infection, a total of 180 male turkey poults were used. The complete experimental procedure was repeated 3 times to obtain consistent results. In each experiment, 60, 1 day-old poults were divided into four groups consisting of 15 birds each. Birds were placed in wire-floored cages measuring 50 × 50 cm, with an independent supply of water and food and elevated approximately 50 cm above the litter. A total of 5 birds were placed in one cage and 3 cages were used for each group. During the experimental period, birds were given balanced commercial starter ration and water *ad-libitum* from 0 to 42 day of age. Animals in Groups 2, 3 and 4 were infected, intra crop through stomach tube, with a single dose of 500 embryonated eggs of *H. gallinarum* 1 day after hatching of turkey poults, according to Permin et al. (1997). Birds in Groups 1 and 2 were fed with food and water free of anthelmintic compounds (non-medicated control birds). Group 1 was considered as the negative control group (non infected, non medicated) and Group 2 was taken into account as the positive control group (infected, non medicated). 25 days post infection, birds in Groups 3 and 4 (medicated birds) received anthelmintic compounds in drinking water for 3 consecutive days. Group 3 was treated with ABZ suspension 2.5% (Arabcomed Co, Egypt) in a dose of 20 mg/kg B. wt; whereas, Group 4 received crude aqueous extract of *A. herba-alba* (ACEA) in a dose of 0.4 g/kg B. wt. ACEA was prepared by using the soaking method of the shoots (leaves and stems).

The shoots at a dose of 0.4 g/kg B. wt. were soaked in a known volume of distilled water for 24 h (Marrif et al., 1995), then sieved (stock). The dose for one day was calculated using the formula: $\text{Dose} = 0.4 \times \text{average weight of birds at the day of treatment} \times \text{number of birds}$. Birds were starved overnight prior to treatment with the drug the following morning. The drug was dissolved in the drinking water and made available over a 6 to 8 h period. The clinical signs were recorded. After slaughtering, the intestinal tract was examined and PM lesions were recorded. Egg counts per gram (EPGs) were determined in excreta samples taken from each subgroups at days 25 and 32 of age (just before treatment and 7 days post treatment, respectively) to evaluate the degree of infestation using modified McMaster technique (Thienpont et al., 1986).

The numbers of adult worms were recorded in five sacrificed poults (per group) on the 25th day post-infestation (before treatment) as well as on the 7th day after treatment according to Permin and Hansen (1998). Feed conversion ratio (FCR) values were calculated weekly as the ratio of feed intake to weight gain. The mean weight gain (MWG) was calculated using the formula:

$$\text{MWG} = (\text{mean final weight of live parakeets birds in a cage}) - (\text{mean initial weight of all parakeets birds in that cage}) + (\text{weight of dead parakeets birds}).$$

The group feed conversion ratio (FCR) for the study period was calculated using the formula:

$$\text{FCR} = \frac{\text{feed consumed per group (g)}}{\text{weight gain of surviving birds} + \text{weight gain of dead birds}}.$$

Individual FCR were not calculated as animals were fed as a group. At day 32 of age, seven days post treatment, 5 birds per group were sacrificed for detection of post mortem lesions and getting liver specimens which immediately fixed in 10% neutral buffered formalin. Paraffin sections were stained with hematoxylin and eosin (H&E) and examined microscopically according to Bancroft et al. (1996).

Biochemical analysis

Blood samples were collected from the wing vein of 5 birds per group on the 7th day post treatment. Each sample was allowed to separate the serum and kept at -20°C till biochemical analysis. Several tests were performed for determination of the serum Alanine aminotransferase (ALT), Aspartate aminotransferase (AST) enzyme activity (Reitman and Frankel, 1957), total protein (Weichselbaum, 1946), albumin (Doumas, 1971), globulins (difference between total protein and albumin), serum uric acid (Haisman and Muller, 1977), and creatinine (Husdan and Rapaport, 1968).

Data analysis

The differences among experimental treatments were tested at $P \leq 0.05$ by one-way ANOVA according to Duncan (1955) and Snedecor and Cochran (1969) using the SPSS program (SPSS v.11, SPSS 1986).

RESULTS

Once infected it took approximately 14 days for the birds to demonstrate clinical signs of infection. The observed clinical signs were depression (fluffed up feathers, appetite loss, irritability, and feather plucking), dullness, loss of appetite, emaciation and unthriftiness. The necropsy (on the 25th day post-infestation) revealed the presence of adult worms and inflammation of the caeca indicating typhilitis, thickening and nodular formation in the caecal mucosa. There were no mortalities among birds. Seven days post treatment, ABZ and ACEA treated groups were significantly effective ($P \leq 0.05$) in reducing egg outputs, FECRs were 97.31 and 97.78%, respectively, when compared with that of the infected, non medicated group, 0% (Table 1).

In addition, the mean number of worm burden in the medicated groups (Groups 3 and 4) was significantly ($P \leq 0.05$) decreased, WCRs were 95.08 and 96.07%, respectively, when compared with that of the positive control group (Table 2). Body weight, body weight gain and feed conversion ratio values till the age of 21 days did not differ among infected groups (Groups 2, 3 and 4). At the age of 6 weeks, such parameters in turkey poults treated with ACEA were significantly ($P \leq 0.05$) improved

Table 1. Eggs per gram of faeces (EPG) of turkey poult infested with *Heterakis gallinarum* invasive eggs and treated with albendazole suspension and *Artemisia herba-alba* aqueous extract.

Age in days	Group 1 -ve control	Group 2 +ve control	Group 3 ABZ	Group 4 ACAE	LSD
25 days	0.00± 0.00 ^b	153.00± .65 ^a	154.50± 2.61 ^a	153.42± 2.84 ^a	153.00*
32 days	0.00± 0.00 ^c	157.67± 2.66 ^a	4.25±0.46 ^b	3.50±1.68 ^{bc}	4.25*
Production (%)	0	100	2.70	2.22	
FECR (%)	0	0	97.31	97.78	

Eggs per gram faeces (No. X 1000); (Mean ± SE, n = 12); Data were analyzed by one way ANOVA. LSD: least significance difference among means at P ≤ 0.05. Means with different alphabetical superscripts in the same row are significantly different. ABZ: albendazole. ACAE: crude aqueous extract of *Artemisia herba-alba*. 25 days (just before treatment); 32 days (7 days post treatment). FECR= Reduction % of fecal egg count

Table 2. Worm burden of turkey poult infested with *Heterakis gallinarum* invasive eggs and treated with albendazole suspension and *Artemisia herba-alba* aqueous extract.

Age in days	Group 1 -ve control	Group 2 +ve control	Group 3 ABZ	Group 4 ACAE	LSD
25 days	0.00± 0.00 ^b	67.20 ± 1.86 ^a	66.40 ± 0.81 ^a	66.20 ± 2.13 ^a	66.20 *
32 days	0.00± 0.00 ^c	61.00 ± 0.71 ^a	3.00± 0.32 ^b	2.40 ± 0.25 ^b	2.40 *
Production (%)	0	100	4.92	3.93	
WCR (%)	0	0	95.08	96.07	

(Mean ± SE, n = 5); Data were analyzed by one way ANOVA. LSD: least significance difference among; means at P ≤ 0.05. Means with different alphabetical superscripts in the same row are significantly different. ABZ: albendazole; ACAE: crude aqueous extract of *Artemisia herba-alba*. 25 days (just before treatment); 32 days (7 days post treatment). WCR= Reduction % of worm count.

when compared with those of the positive control and albendazole treated groups (Table 3). Among ABZ treated group, some biochemical parameters were significantly (P ≤ 0.05) altered when compared with those of the other groups (Groups 1, 2 and 4). Such alterations included reduction in the total protein, globulin and albumin levels and elevation of the levels of ALT, AST, creatinine and uric acid (Table 4).

Microscopically, male *H. gallinarum* infested the caeca of turkey poult is very conspicuous with two unequal spicules (Figure 1). Histological sections of the liver of turkey poult treated with ABZ revealed mild vacuolar degeneration of the hepatocytes and moderate numbers of mixed inflammatory cells in sinusoids (Figure 2). Whereas those of the treated group with ACAE indicated normal histological appearance of the hepatocytes (apparently healthy) and low numbers of inflammatory cells in sinusoids (Figure 3).

DISCUSSION

The infestation of turkey poult with *H. gallinarum*, in this study, appeared to cause depression, dullness, emaciation, dehydration and lower locomotion. In addition, cross sections of cecum of infected turkey poult indicated the presence of *H. gallinarum* and inflammatory reaction of the submucosa. Similar observations were reported (Brener et al., 2006).

Pathological changes included congestion, hemorrhages and nodules with necrotic center in the caecum were noted. Alike lesions were recorded (Choudury and Das, 1993; Roberts and Janovy, 2005; Menezes et al., 2003; Brener et al., 2006). Because of the longevity of the eggs, 4 years, it is difficult to eliminate *H. gallinarum* from a domestic flock. Although adult chickens may affect a self-cure, infective eggs are available for the following spring, when new chicks hatch. Furthermore, as earth worms feed in contaminated soil, they accumulate large numbers of juveniles, which in turn cause massive infections in unlucky birds that eat them (Roberts and Janovy, 2005). Generally speaking, *H. gallinarum* is not highly pathogenic in itself. However, *H. meleagridis*, is transmitted between birds within eggs of *H. gallinarum* (Long et al., 1987) leading to histomoniasis which cause necrosis of the caecal mucosa, swelling of the caecum and liver necrosis (Papini and Cacciuttoli, 2008).

Consequently, reducing the number of eggs in litter through treatment of anthelmintics, is a highly desirable feature which should be taken into account in the control of ascaridiasis that is characterized by high biotic potential and large number of eggs which may accumulate in deep letter houses (Davis and Jayner, 1955). Concerning conventional anthelmintics, our results indicated that ABZ was highly effective in controlling *H. gallinarum* as FECR was 97.31% and WCR was 95.08%. Analogues to our result, ABZ in a single dose of 20 mg/kg B. wt. is highly effective in the treatment of chickens for

Table 3. Growth performance parameters of turkey poultz infested with *Heterakis gallinarum* invasive eggs and treated with albendazole suspension and *Artemisia herba-alba* aqueous extract.

Time (days)	Growth performance parameters	Group 1 -ve control	Group 2 +ve control	Group 3 ABZ	Group 4 ACAE	LSD
1 day old	Body weight	65.67 ± 0.95 ^a	66.87 ± 0.96 ^a	45.20 ± 2.90 ^a	65.93 ± 0.90 ^a	NS
7 day old	Body weight	239.33 ± 0.86 ^a	231.47 ± 1.03 ^b	233.83 ± 1.39 ^b	233.13 ± 1.38 ^b	5.40*
	Body gain	171.53 ± 1.91 ^a	162.60 ± 1.57 ^b	164.87 ± 0.85 ^b	166.13 ± 1.39 ^b	5.40*
	FCR	1.31 ± 0.01 ^a	1.33 ± 0.01 ^a	1.32 ± 0.02 ^a	1.32 ± 0.01 ^a	NS
14 day old	Body weight	449.40 ± 1.81 ^a	356.88 ± 1.46 ^b	358.33 ± 2.17 ^b	353.60 ± 2.01 ^b	91.10*
	Body gain	215.60 ± 2.36 ^a	137.47 ± 2.03 ^b	133.33 ± 1.89 ^b	132.93 ± 1.40 ^b	78.13*
	FCR	1.35 ± 0.01 ^b	1.58 ± 0.02 ^a	1.58 ± 0.01 ^a	1.57 ± 0.01 ^a	0.23*
21 day old	Body weight	770.20 ± 1.83 ^a	556.87 ± 4.19 ^b	549.33 ± 3.18 ^b	549.00 ± 3.14 ^b	213.33*
	Body gain	320.80 ± 3.03 ^a	191.20 ± 3.35 ^b	192.27 ± 2.68 ^b	193.93 ± 2.78 ^b	127.87*
	FCR	1.54 ± 0.02 ^b	2.41 ± 0.03 ^a	2.39 ± 0.03 ^a	2.41 ± 0.02 ^a	0.86*
28 day old	Body weight	1261.67 ± 5.18 ^a	757.47 ± 2.82 ^c	947.33 ± 8.09 ^b	951.27 ± 8.45 ^b	189.87*
	Body gain	491.53 ± 4.67 ^a	200.47 ± 5.49 ^c	398.73 ± 7.69 ^b	401.13 ± 8.04 ^b	90.40*
	FCR	1.55 ± 0.01 ^c	2.43 ± 0.02 ^a	1.87 ± 0.02 ^b	1.87 ± 0.02 ^b	0.32*
35 day old	Body weight	1814.13 ± 6.87 ^a	1049.47 ± 10.94 ^c	1406.00 ± 6.85 ^b	1415.33 ± 8.27 ^b	356.53*
	Body gain	545.87 ± 5.99 ^a	290.60 ± 12.34 ^c	458.67 ± 8.02 ^b	465.40 ± 8.67 ^b	80.47*
	FCR	1.57 ± 0.02 ^d	2.58 ± 0.03 ^a	1.92 ± 0.02 ^b	1.81 ± 0.03 ^c	0.11*
42 day old	Body weight	2754.67 ± 6.24 ^a	1392.00 ± 15.19 ^d	2235.33 ± 7.41 ^c	2292.34 ± 7.79 ^b	36.00*
	Body gain	947.20 ± 4.80 ^a	323.27 ± 18.48 ^d	829.00 ± 9.24 ^c	867.33 ± 8.85 ^b	38.33*
	FCR	1.61 ± 0.01 ^d	2.41 ± 0.04 ^a	1.88 ± 0.01 ^b	1.70 ± 0.02 ^c	0.10*

Mean ± SE, n = 15; Data were analysed by one-way ANOVA. ACAE: crude aqueous extract of *Artemisia herba-alba*. ABZ: albendazole; LSD: least significance difference among means at P ≤ 0.05, NS = non significant; Body gain (g); Means with different alphabetical superscripts in the same row are significantly different.

H. gallinarum and *A. galli* as its efficacies for controlling larvae and adult burden were 98.9 and 94.9% for *H. gallinarum* and 98.2 and 100% for *A. galli*, respectively (Tucker et al., 2007). Phenothiazine is effective against *H.*

gallinarum, *in vitro* (Oliver, 1953). Unfortunately, the increasing prevalence of anthelmintic resistant strains of helminths (Walter and Prichard, 1985; Kaplan, 2004; Beech et al., 2011), for example albendazole resistance in gastrointestinal

nematode parasites (Hoque et al., 2003; Borgsteede et al., 2007) has been developed. Many great research challenges and prospects for the identification of new, safe and environmentally acceptable anthelmintics such as medicinal plants

Table 4. Biochemical parameters of turkey poult infested with *Heterakis gallinarum* invasive eggs and treated with albendazole suspension or *Artemisia herba-alba* aqueous extract.

Parameters	Group 1 -ve control	Group 2 +ve control	Group 3 ABZ	Group 4 ACAE	LSD
ALT (IU/L)	18.80± 0.31 ^b	18.15± 0.27 ^b	21.10 ± 0.29 ^a	19.04 ± 0.30 ^b	5.94*
AST (IU/L)	217.58± 0.96 ^b	218.25± 2.16 ^b	262.40 ± 2.33 ^a	221.70± 2.42 ^b	42.26*
Total protein (gm/dl)	4.34± 0.20 ^a	4.35 ± 0.21 ^a	3.40 ± 0.17 ^b	4.86 ± 0.13 ^a	0.78*
Serum albumin (gm/dl)	1.62 ± 0.06 ^a	1.75 ± 0.06 ^a	0.59 ± 0.06 ^b	1.16 ± 0.14 ^a	0.50*
Serum globulin (gm/dl)	2.72± 0.07 ^b	2.60± 0.05 ^b	2.81 ± 0.08 ^b	3.70 ± 0.07 ^a	0.89*
Creatinine (IU/L)	0.08 ± 0.01 ^b	0.07 ± 0.005 ^b	0.11 ± 0.009 ^a	0.07 ± 0.004 ^b	0.02*
Uric acid (mg/dl)	3.40± 0.21 ^b	3.59± 0.22 ^b	5.40± 0.35 ^a	3.70± 0.18 ^b	1.60*

Mean ± SE, n = 5; Data were analysed by one-way ANOVA. ACAE: crude aqueous extract of *Artemisia herba-alba*. ABZ: albendazole; LSD: least significance difference among means at P ≤ 0.05. Means with different alphabetical superscripts in the same row are significantly different.

are very crucial.

Treatment with ABZ and ACAE, in this study, indicated high FECR, 97.31 and 97.78%, respectively, and worm burden was significantly reduced (95.08 and 96.07%) in both medicated groups (ABZ and ACEA, respectively) than that of the positive control groups. Similar to our results, complete reduction of egg production (100%) has been recorded for ACAE against *A. galli* infecting chickens (Seddiek et al., 2007) and *Artemisia cina* against *Moniezia* spp. infecting sheep (Bashtar et al., 2011). Lower FECR (67.2%) has been recorded after treatment of different species of nematodes in naturally infested sheep with *Artemisia brevifolia* crude aqueous extract (CAE) (Iqbal et al., 2004). *A. herb- alba* possesses several constituents that induced anthelmintic effect, such as santonin (Khafagy et al., 1971) and eight polyphenolics and related constituents (Mohamed et al., 2010). Synthetic phenolic anthelmintics interfere with the energy generation in the helminth parasites by uncoupling the oxidative phosphorylation. Another possible mechanism of action is that they bind to free proteins in the gastrointestinal tract of the host animal or to glycoprotein on the cuticle of the parasite and cause death (John et al., 2009).

Additionally, plant possess “antioxidant activity” (Mohamed et al., 2010) which is capable of reducing the nitrate generation which could interfere in local homeostasis which is essential for the development of helminthes (Borba et al., 2010). Similar to our results, methanolic extract of *Caesalpinia crista* Linn. seeds and piperazine (200 mg/kg) are equieffective, *in vivo*, in treating *A. galli* infecting chickens (Javed et al., 1994). Several anthelmintic plants are effective *in vitro*, such as *A. sativum* has shown anthelmintic action against *H. gallinarum* and *A. galli* (Nagaich, 2000); *Carica papaya*, *Sapindus trifoliatus*, *Butea frondosa* and *Momordica charantia* were more effective against *A. galli* than piperazine hexahydrate (Lal et al., 1976); and aqueous and ethanolic extracts of *Morinda citrifolia* fruit (noni) were effective against *A. galli* (Brito et al., 2009). Use of *A. galli* and *Raillietina* species as a suitable model for

screening of anthelmintic drug was advocated earlier (Kaushik et al., 1974). Furthermore, several assays were performed *in vitro* using adult earthworm (*Pheretima posthuma*) for preliminary evaluation of anthelmintic activity, owing to its anatomical and physiological resemblance with the intestinal roundworm parasites, such as *Ascaris lumbricoids*, of human beings (Dash et al., 2002; Shivkumar and Kumar et al., 2003). Some herbs show *in vitro* anthelmintic activity against *P. posthuma*, tapeworms (*Raillietina spiralis*) and roundworms (*A. galli*) such as the aqueous extract of *Thespesia lampas* (Cav.) roots (Kosalge and Fursule, 2009) and crude extracts and fractions of *Pterospermum acerifolium* (Parida et al., 2010). In addition, the crude alcohol and aqueous extracts of the seeds of *Cleome viscosa*. Linn. shows anthelmintic activity against *P. posthuma* and *A. galli* (Mali et al., 2007). Santonin present in *A. herb- alba* (Khafagy et al., 1971) induces an anthelmintic effect. The vermifuge effect of santonin substance, prepared from the *Artemisia* spp., induced changes in the musculocutaneous sac (cuticle, hypoderm and muscle cells) of the worm through its direct action on muscle cells of the worm resulting in complete relaxation of its muscular layer leading to its expulsion to outside (Rachkovskaia, 1978).

Akhtar et al. (1982) reported that the percentage reduction in EPG counts in the calves naturally acquired *Neoscaris vitulorum* and treated with 15 mg/kg of santonin on the seventh day, these values were 100, 100 and 99.7% in moderate, high and heavily infected calves, respectively. Both piperazine and santonin were associated with some side effects like diarrhea, restlessness, etc. Santonin has an efficacy similar to piperazine given at the 88 mg/kg dose level for the treatment of ascariasis in buffalo calves. Low concentrations of santonin are reported to have a selective toxic action on the ganglion located in the nerve ring of *Ascaris* spp. (Sollman, 1957). Against other nematodes, such as *Oxyuris* spp and cestodes, santonin is not effective (Steinegger and Hänsel, 1972). With regard to weight performances, the present study

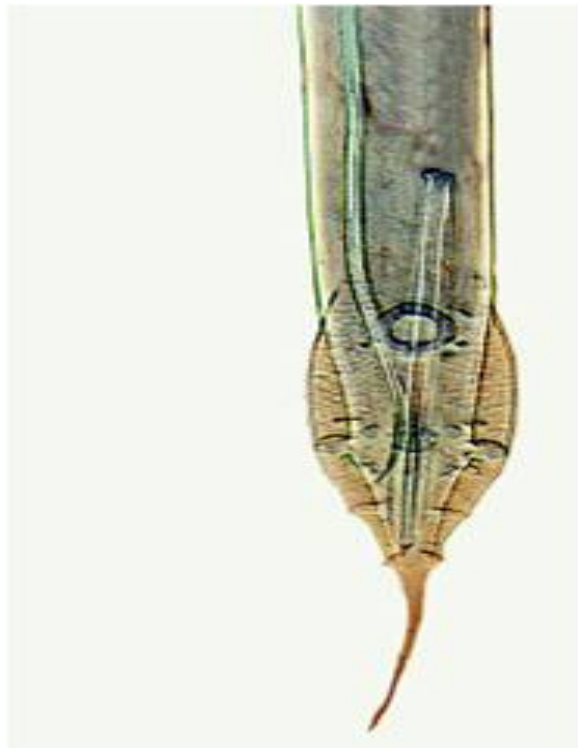


Figure 1. Posterior end of *H. gallinae* adult worm (male), ventral view, infesting the caecum of turkey poult showing two unequal spicules.

indicated that infection with *H. gallinarum* significantly reduced body weight, body gain and increased FCR values highlighting the detrimental effect of the infection with this parasite on the performance of poults.

Similarly, reduction of growth performance in chickens of 2 weeks PI had been recorded (Choudury and Das, 1993). ABZ and ACEA treatments exerted beneficial effects by significantly improving body weight gain and feed conversion ratio values compared to the positive control group. Moreover, ACEA significantly ($P \leq 0.05$) enhanced growth performance of turkey poults than that of ABZ. Comparable to our results, *A. herba-alba* improved the growth performance of chickens infested with *A. galli* (Seddiek et al., 2007) and chickens fed on ration contaminated with aflatoxin-B1 (Mobarak et al., 2008). In addition to the anthelmintic effect of the used herb, it improved weight performances indirectly because of its other biological activities. *A. herba-alba* improves the general health of infected turkeys because it possess antibacterial (Yashphe et al., 1979; Juteau et al., 2002; Laid et al., 2008; Elturbi et al., 2011), anti-oxidant (Aniya et al., 2000; Juteau et al., 2002; Kim et al., 2003; Kadri et al., 2011), and antifungal activities (El-Shayeb and Mabrouk, 1984; Saleh et al., 2006).

Moreover, *A. herba-alba* is used for digestive disorders, abdominal pain, colic and liver failure (Le Floc'h, 1983). Moreover, santonin induces significant antipyretic, anti-

inflammatory effect and inhibit granuloma formation (Al-Harbi et al., 1994). Ideally, plants should provide, besides the anthelmintic effect, an alternative source of nutrition for animals of *A. herba-alba* is also suggested to be important as a fodder for sheep and for livestock in the plateau regions of Algeria where it grows abundantly (Benmansur et al., 1990; Fenardji et al., 1994; Benmansour and Taleb-Bendiab, 1998).

The liver of turkey poults treated with ABZ showed vacuolar degeneration in the hepatocytes indicating the toxic effect of ABZ on the liver cells, meanwhile the liver of turkey poults treated with ACEA showed no degenerative changes in hepatocytes which seem apparently healthy. The histopathological results ensured that ACEA has no adverse effect on hepatocytes. Biochemical analysis in the present study indicated the side effect of treatment with albendazole, for example reduction in the total protein and albumin levels and elevation of the levels of serum ALT and AST enzymes, when compared with that of ACEA medicated group. This may be due to side (toxic) effect of ABZ on the liver cells. Similar results were recorded in human (Choi et al., 2008) and in rat (Abd El-Rahman et al., 1999). Our results indicated that ACEA has no side effect on the liver cells. *A. herba-alba* has hepatoprotective effect (Aniya et al., 2000; Israpil et al., 2002) and it enhances bilirubin clearance (Mobarak et al., 2008). The adverse effect of ABZ on kidney functions has been confirmed by the elevated levels of creatinine and uric acid. Such elevation was not recorded for ACEA. A comparable result has been recorded for *A. herba-alba* (Marrif et al., 1995). A single dose of ABZ is safe and no adverse effects were observed on bird appearance, behavior, apparent appetite and weight gain (Tucker et al., 2007). Although ABZ is one of the most important antiparasitic drugs with high margin of safety, some unwanted side effects cannot be ignored (Abd El-Rahman et al., 1999). The adverse effect of ABZ in Group 3 on the liver and kidney functions and tissue may be due to the use of ABZ for somewhat longer time, to imitate what farmers in Egypt do to ensure that all birds get treated, than that recommended by the producer (20 mg/kg B. wt. for 3 successive days instead of a single dose).

The increase of ALT and AST enzymes was obtained in rat given ABZ in a dose of 400 mg/kg B. wt. as a single dose (Abd El-Rahman et al., 1999). Moreover, birds of the order Columbiformes, such as pigeon and dove, are susceptible to toxicosis after ABZ and fenbendazole (FBZ) administration (Howard et al., 2002). Regarding the nematicidal activity of *A. herba-alba*, ACEA "eradicate" intestinal infection with *Enterobius vermicularis* within 3 days in all 10 patients treated (Al-Waili, 1988). Ascaridae from hogs and ground worms were killed by the oil of the Libyan *A. herba-alba* in a short time (Callegari and Rossi, 1939, 1940). The powdered shoots of *A. herba-alba* expressed anthelmintic activity against experimental haemonchosis in Nubian goats which manifested by the

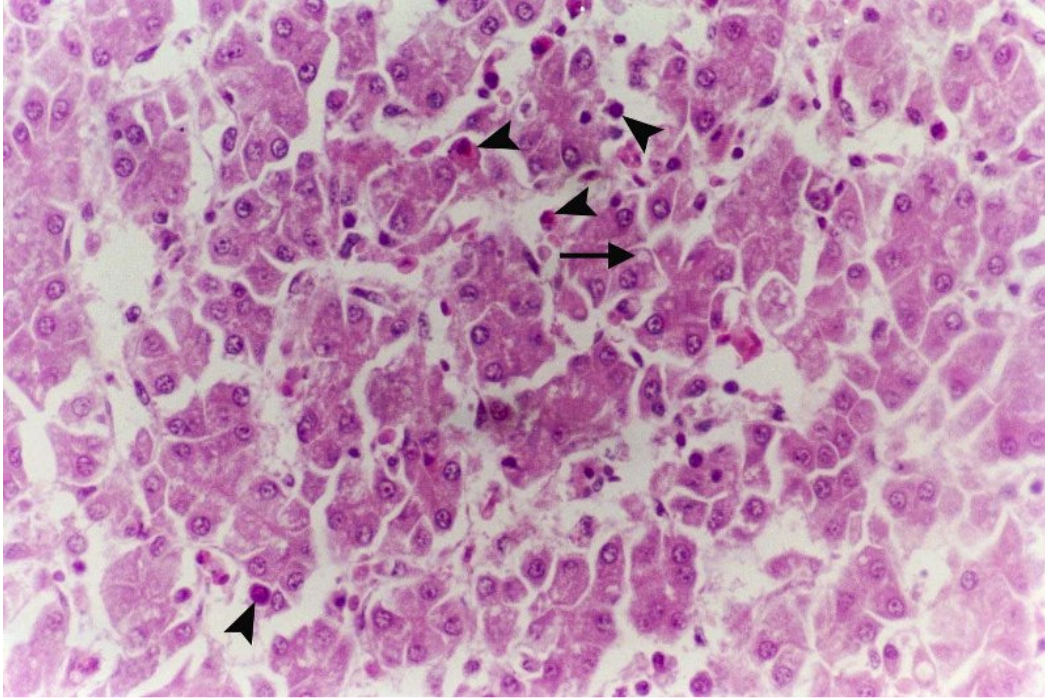


Figure 2. Liver of turkey poults infected with *H. gallinae* and treated with albendazole suspension (2.5%) showing mild vacuolar degeneration (arrow) of the hepatocytes and moderate numbers of mixed inflammatory cells (arrow head) in sinusoids stained with hematoxylin and eosin (X 400).

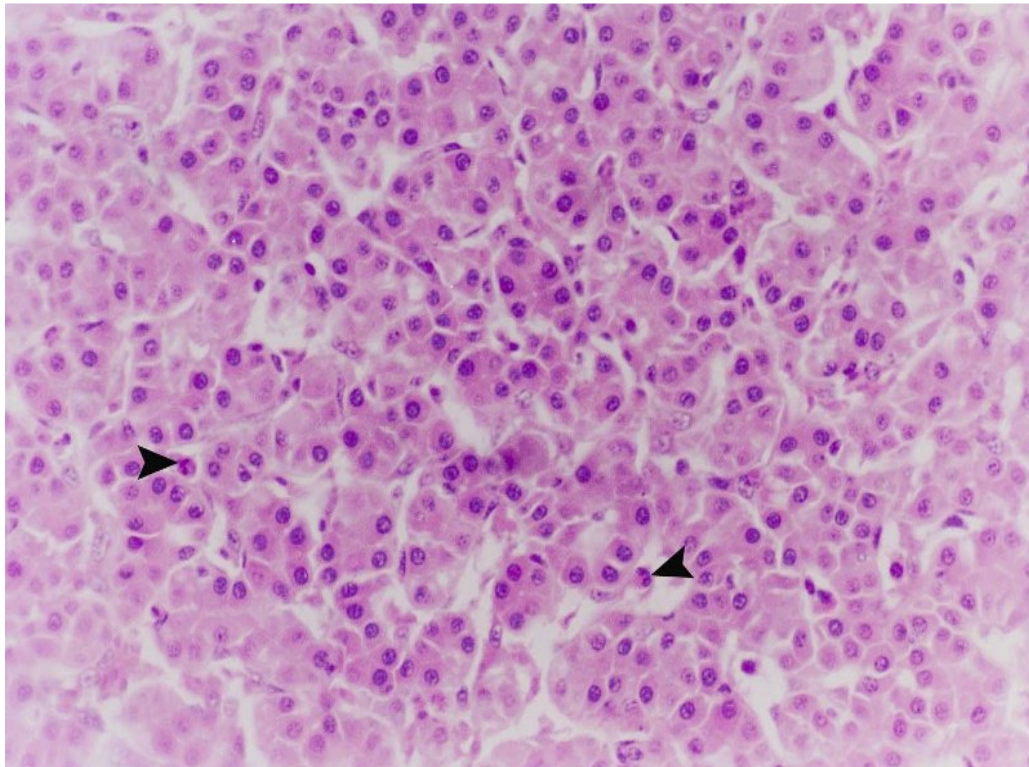


Figure 3. Liver of turkey poults infected with *H. gallinae* and treated with *A. herba-alba* extract showing normal histological appearance of the hepatocytes and low numbers of inflammatory cells (arrow head) in sinusoids stained with hematoxylin and eosin (X 400).

absence of eggs in the faeces or adult worms in the abomasum at necropsy and of significant lesions in the tissues of the goats and return of the concentrations of serum ammonia, sodium, potassium, total protein, creatinine and aspartate aminotransferase (GOT) to normal (Idris et al., 1982). The leaf extract of *A. herba-alba* was the most effective among twenty Jordanian plant species against two species of root-knot nematodes, *in vitro* (Al-Banna et al., 2003). In addition to its nematicidal activity, *A. herba-alba* induces pesticidal activity as it "induced" larvicidal activity against *Culex pipiens* mosquito, insecticidal activity against houseflies *Musca domestica* L., and rodenticidal activity against white mice *Mus musculus* (Hifnawy et al., 2001). Furthermore, extracts of *A. herba-alba* are highly effective against arthropods of agricultural importance, such as *Tetranychus cinnabarinus* mites (Azaizeh et al., 2007), *Bemisia tabaci* (Gennadius), *Aphis gossypii* (Glover) and *Thrips tabaci* (Lindman) (Soliman, 2006, 2007), *Acanthoscelides obtectus* (Coleoptera: Bruchidae) (Tani et al., 2008), *A. obtectus*, responsible for green beans rot (Derwich et al., 2009) and cotton leafworm *Spodoptera littoralis* (Biosd.) larvae (Hifnawy et al., 2001). Due to narrow therapeutic window (safety index) of and toxicity of *A. herba-alba*, the crude drug santonin is no longer used (Reynolds and Prasad, 1982; Tyler et al., 1988; De Smet, 1997). Fortunately, *A. herba-alba* contains very few amount of santonin, 0.99% w/w (Khafagy, 1971). Like our result that indicated safety of ACEA, it (85 mg/kg) induces hypoglycemic effect and doses did not cause any acute toxicity or behavioral changes in rabbits (Iriadam et al., 2006) and the crude *C. crista* powder appears to be potent and safer than its methanol extract on the basis of the side effects observed (Javed et al., 1994). It is highly advisable that pre- and posttreatment helminth levels be determined in flocks to monitor the levels of parasitism suffered by the birds and to ensure effective removal of parasites by herbal intervention. Efficacies below 90% are not considered therapeutic in the evaluation of anthelmintics for effectiveness (Yazwinski et al., 2003). Impacts of using medicinal plants for GI parasite control can be measured by: increased weight gain, improved FCR, decreased host mortality, reduced use of commercial anthelmintics, decreased EPG and reduced L3 larvae counts in coprocultures (Ketzis et al., 2006). In the present study, it was observed that ACEA was effective and well comparable with the standard drug, ABZ.

Conclusion

A. herba-alba induced anthelmintic effect as it reduced egg shedding and worm burden in the infected birds, in a similar manner to that of albendazole. The herbal extract produced significantly improved FCR over the other infected groups (positive control and albendazole treated

group) and had no adverse effect on liver and kidney of treated poult. Taking together all these findings, we suggest that *A. herba-alba* could be used for controlling heterakid infection as an alternative to standard anthelmintic drugs. Attempts for the isolation and characterization of the active constituents responsible for such activities are currently under progress. Further studies are necessary to understand the exact mechanism of action.

ACKNOWLEDGMENTS

The authors thank Dr. Moustafa, Sh., Head of the Department of Pathology, Faculty of Veterinary Medicine, Benha University, Egypt and Dr. Soliman, A.S., chief researcher of pathology, Animal health research institute, for their cooperation in performing the histopathological part.

REFERENCES

- Abd El-Rahman MA, Abdel-Nabi IM, Omran MA, Mohamed FM (1999). Cytotoxic effects of Albendazole, antiparasitic drug, on the liver of the rat: Subchronic study. *Egypt. J. Biol.*, 1: 16-29.
- Akhtar MS, Chattha MI, Chaudhry AH (1982). Comparative efficacy of santonin and piperazine against *Neoscaris vitulorum* in buffalo calves. *J. Vet. Pharmacol. Ther.*, 5: 71-76.
- Al-Banna L, Darwish RM, Aburjai T (2003). Effect of plant extracts and essential oils on root-knot nematode. *Phytopathol. Mediterr.*, 42: 123-128.
- Al-Harbi MM, Qureshi S, Ahmed MM, Raza M, Miana GA, Shah AH (1994). Studies on the antiinflammatory, antipyretic and analgesic activities of santonin. *Jpn. J. Pharmacol.*, 64: 135-139.
- Al-Waili NS (1988). *Artemisia herba-alba* extract for treating *Enterobius vermicularis* infection. *Trans. Roy. Soc. Trop. Med. Hyg.*, 82: 626.
- Aniya Y, Shimabukura M, Shimoji M, Kohatsu M, Gyamfi MA, Miyagi C, Kunni D, Takayama F, Egashira T (2000). Antioxidant and hepatoprotective actions of the medical herb *Artemisia campestris* from the Okinawa Islands. *Biol. Pharm. Bull.*, 233: 309-312.
- Azaizeh H, Kobaisy M, Dakwar S, Saad B, Shaqir I, Said O (2007). Botanical pesticides as a source of safe bio-acaricides for the control of *Tetranychus cinnabarinus* mites. *Fitoterapia. Acta Phytopathol. Entomol. Hung.*, 42: 143-152.
- Bancroft GD, Steven SA, Tarnal N (1996). *Theory and practice of histopathological technique*, 4th ed. Churchill, Livingstone, Edinburgh, London, Melbourne and New York.
- Bashtar AR, Hassanein M, Abdel-Ghaffar F, Al-Rasheid K, Hassan S, Mehlhorn H, Al-Mahdi M, Morsy K, Al-Ghamdi A (2011). Studies on monieziaosis of sheep I. Prevalence and anthelmintic effects of some plant extracts, a light and electron microscopic study. *Parasitol. Res.*, 108: 177-86.
- Beech RN, Skuce P, Bartley DJ, Martin RJ, Prichard RK, Gilleard JS (2011). Anthelmintic resistance: markers for resistance, or susceptibility? *Parasitol.*, 138: 160-174.
- Benmansour A, Taleb BSA (1998). Comparative investigation of proteins and amino acids in *Artemisia herba-alba* residues and Algerian date stones. Proposal to use them as additional feed for livestock. *J. Soc. Alger. Chim.*, 8: 67-71.
- Benmansour A, Taleb BSA, Mashev N, Vasilev G (1990). Studies on the chemical composition of *Artemisia (Artemisia herba-alba)*. *Doklady Bolgarskoi Akademii Nauk.*, 43: 65-67.
- Borba HR, Freire RB, Albuquerque AC, Cardoso MEO, Braga IG, Almeida STP, Ferreira MJC, Fernandes G LT, Camacho ACL, Lima RC, Almeida ACC, Mattos DMM, Duarte RM, Nascimento

- SF, Framil RA, Dire GF (2010). Anthelmintic comparative study of *Solanum lycocarpum* St. Hill extracts in mice naturally infected with *Aspiculuris tetraptera*. *Nat. Sci.*, 8: 94-100.
- Borgsteede FHM, Dercksen DD, Huijbers R (2007). Doramectin and albendazole resistance in sheep in The Netherlands. *Vet. Parasitol.*, 144: 180 - 183. doi:10.1016/j.vetpar.2006.09.031.
- Brener B, Tortelly R, Menezes RC, Pereira LCM, Pinto RM (2006). Prevalence and pathology of the nematode *Heterakis gallinae*, the trematode *Paratanaisia bragai*, and the protozoan *Histomonas meleagridis* in the Turkey, *Meleagris gallopavo*. *Men. Inst. Oswaldo Cruz, Rio de Janeiro.* 101: 677-681.
- Brito DR, Fernandes RM, Fernandes MZ, Ferreira MD, Rolim FR, da Silva Filho ML (2009). Anthelmintic activity of aqueous and ethanolic extracts of *Morinda citrifolia* fruit on *Ascaridia galli*. *Braz. J. Vet. Parasitol.*, 18: 32-36.
- Callegari L, Rossi A (1939). The active principles of Lybian *Artemisia herba-alba* and their pharmacological action. *Arch. Ital. Sci. Farmacol.*, 8: 145-60.
- Callegari L, Rossi A (1940). The active principles of Lybian *Artemisia herba-alba* and their pharmacological action. *Chim. Ind. Paris*, 44: 321.
- Caner A, Döşkaya M, Değirmenci A, Can H, Baykan S, Uner A, Başdemir G, Zeybek U, Gürüz Y (2008). Comparison of the effects of *Artemisia vulgaris* and *Artemisia absinthium* growing in western Anatolia against trichinellosis (*Trichinella spiralis*) in rats. *Exp. Parasitol.*, 119: 173-179.
- Choi GY, Yang HW, Cho SH, Kang DW, Go H, Lee WC, Lee YJ, Jung SH, Kim AN, Cha SW (2008). Acute drug-induced hepatitis caused by Albendazole. *J. Kor. Med. Sci.*, 23: 903-905.
- Choudury S, Das MR (1993). Studies on growth rate and pathological changes in chickens experimentally infected with *Heterakis gallinarum*. *J. Vet. Parasitol.*, 7: 81-85.
- Dash GK, Suresh P, Kar DM, Ganpaty S, Panda SB (2002). Evaluation of *Evolvulus alsinoides* Linn. for anthelmintic and antimicrobial activities. *J. Nat. Rem.*, 2: 182-185.
- De Smet PAGM (1997). *Adverse Effects of Herbal Drugs*. Springer-Verlag, Berlin Heidelberg New York.
- del Cacho E, Gallego M, Francesch M, Quílez J, Sánchez-Acedo C (2010). Effect of artemisinin on oocyst wall formation and sporulation during *Eimeria tenella* infection. *Parasitol. Intern.*, 59: 506-511. doi:10.1016/j.parint.2010.04.001.
- Derwich E, Benziane Z, Boukir A (2009). Chemical compositions and insecticidal activity of essential oils of three plants *Artemisia sp: Artemisia herba-alba, Artemisia absinthium* and *Artemisia pontica* (morocco). *Ejeafche*, 8: 1202-1211.
- Doumas B (1971). Colorimetric method for albumin determination. *Clin. Chim. Acta*, 31: 87-92.
- Duncan DR (1955). Multiple range and multiple F tests. *Biometrics*, 11: 31-42.
- El-Garhy MF, Mahmoud LH (2002). Anthelmintic efficacy of traditional herbs on *Ascaris lumbricoides*. *J. Egypt. Soc. Parasitol.*, 32: 893-900.
- Ene AC, Atawodi SE, Ameh DA, Ndukwe GI, Kwanashie HO (2009). Bioassay-guided fractionation and *in vivo* antiplasmodial effect of fractions of chloroform extract of *Artemisia maciverae* Linn. *Acta Trop.*, 112: 288-294.
- El-Shayeb NMA, Mabrouk SS (1984). Utilization of some edible and medicinal plants to inhibit aflatoxin formation. *Nutr. Rep. Intern.*, 29: 273-282.
- ElturbiG JA, SufyaG NM, EllafiG AM (2011). Phytochemical Investigation of *Artemisia Herba Alba Asteraceae*. *Al- satil J.*, 85-95.
- Fenardji F, Klur M, Furlon Mrs C, Ferrando R (1974). White *artemisia, (Artemisia herba-alba)*. *Revue Elev. Méd. Vét. Pays Trop.*, 27: 203-206.
- Friedman J, Yaniv Z, Dafni A, Palewitch D (1986). A preliminary classification of the healing potential of medicinal plants, based on a rational analysis of an ethnopharmacological field survey among Bedouins in the Negev desert, Israel. *J. Ethnopharmacol.*, 16: 275-287.
- Haisman P, Muller BP (1977). *Glossary of clinical chemistry and terms*. Butter worth, London, p. 126.
- Harper GC, Makatouni A (2002). Consumer perception of organic food production and farm animal welfare. *Br. Food J.*, 104: 287-299.
- Hatimi S, Boudouma M, Bichichi M, Chaib N, Idrissi NG (2001). Evaluation *in vitro* antileishmanial activity of *Artemisia herba-alba* Asso. *Therapeutic, Bull. Soc. Pathol. Exot.*, 94: 29-31.
- Hifnawy MS, Rashwan OA, Rabeh MA (2001). Comparative chemical and biological investigations of certain essential oils belonging to families Asteraceae, Lamiaceae and Graminae. *Bull. Fac. Pharm. Cairo Univ.*, 39: 35-53.
- Homer BL, Butcher GD (1991). Histomoniasis in leghorn pullets on a Florida farm. *Avian Dis.*, 35: 621-624.
- Hoque MN, Begum N, Nooruddin M (2003). Albendazole Resistance in Gastrointestinal Nematode Parasites of Cattle in Bangladesh. *Trop. Anim. Health Prod.*, 35: 219-222.
- Howard LL, Papendick R, Stalis IH, Allen JL, Sutherland-Smith M, Zuba JR, Ward DL, Bruce A, Rideout RA (2002). Fenbendazole and Albendazole Toxicity in Pigeons and Doves. doi: 10.1647/1082-6742(2002)016(0203:FAATIP)2.0.CO;2. *J. Avian Med. Surg.*, 16:203-210.
- Husdan H, Rapaport A (1968). Chemical determination of creatinine with depolarization. *Clin. Chem.*, 14: 222-238.
- Idris UE, Adam SE, Tartour G (1982). The anthelmintic efficacy of *Artemisia herba-alba* against *Haemonchus contortus* infection in goats. *Natl. Inst. Anim. Health Q.*, 22: 138-143.
- Ikeme MM (1971). Weight changes in chickens placed on different levels of nutrition and varying degrees of repeated dosage with *Ascaridia galli* eggs. *Parasitol.*, 63: 251-260.
- Iqbal Z, Lateef M, Ashraf M, Jabbar A (2004). Anthelmintic activity of *Artemisia brevifolia* in sheep. *J. Ethnopharmacol.*, 93: 265-268.
- Iriadam M, Musa D, Gümühan H, Baba F (2006). Effects of two Turkish medicinal plants *Artemisia herba-alba* and *Teucrium polium* on blood glucose levels and other biochemical parameters in rabbits. *J. Cell Mol. Biol.*, 5: 19-24.
- Israpil I, Abdiryim A, Gulnar G (2002). Experimental study on liver protective effect of *Artemisia rupestris* extract. *Zhongguo Zhong Xi Yi Jie He Za Zhi* 22: 126-128.
- Jansson D, Fossum O, Engelsen PE, Christesson B, Anderson B, Christesson D (2004). Parasitoforekomst of tamhous in Swedish backyard flocks. *Sven. Veterinartidn.*, 56: 11-17.
- Javed I, Akhtar MS, Rahman ZU, Khaliq T, Ahmad M (1994). Comparative anthelmintic efficacy and safety of *Caesalpinia crista* seed and piperazine adipate in chickens with artificially induced *Ascaridia galli* infection. *Acta. Vet. Hung.*, 42: 103-109.
- John J, Mehta A, Shukla S, Mehta PA (2009). Report on anthelmintic activity of *Cassia tora* leaves. *J. Sci. Technol.*, 31: 269-271.
- Juteau F, Masotti V, Bessiere JM, Dherbomez M, Viano J (2002). Antibacterial and antioxidant activities of *Artemisia annua* essential oil. *Fitoterapia*, 73: 532-535.
- Kadri A, Chobba IB, Zarai Z, Békir A, Gharsallah N, Damak M, Gdoura R (2011). Chemical constituents and antioxidant activity of the essential oil from aerial parts of *Artemisia herba-alba* grown in Tunisian semi-arid region. *Afr. J. Biotechnol.*, 10: 2923-2929.
- Kaemmerer K, Butendotter S (1973). The problem of residues in meat of edible domestic animals after application or intake of organophosphate esters. *Residue. Rev.* 46: 1.
- Kaplan RM (2004). Drug resistance in nematodes of veterinary importance. *Trends Parasitol.*, 20: 477-481.
- Kaushik RK, Katiyar JC, Sen AB (1974). Studies on the mode of action of anthelmintics with *Ascaridia galli* as a test parasite. *Indian J. Med. Res.*, 64: 1367-1375.
- Ketzis JK, Vercruysse J, Stromberg BE, Larsen M, Athanasiadou S, Houdijk JGM (2006). Evaluation of efficacy expectations for novel and non-chemical helminth control strategies in ruminants. *Vet. Parasitol.*, 139: 321-335.
- Khafagy SM, Gharbo SA, Sarg TM (1971). Phytochemical investigation of *Artemisia herba alba*. *Planta Med.*, 20: 90-96. DOI: 10.1055/s-0028-1099670.
- Khater HF (1993). Some studies on enteric helminths parasites of poultry. Master Thesis. Zagazig University, Benha Branch, Egypt.
- Khater HF (2003). Biocontrol of some insects. Ph.D Thesis, Zagazig University, Benha Branch, Egypt.
- Khater HF, Shalaby AA (2008). Potential of biologically active plant oils

- for control mosquito larvae *Culex pipiens* (Diptera: Culicidae) from an Egyptian locality. Rev. Inst. Med. Trop. S. Paulo, 50: 107-112.
- Khater HF, Khater DH (2009). The insecticidal activity of four medicinal plants against the blowfly *Lucilia sericata* (Diptera: Calliphoridae). Intern. J. Dermatol., 48: 492-497.
- Khater HF, Ramadan MY, El-Madawy RS, Abdel-Mageed AD (2009). The lousicidal, ovicidal, and repellent efficacy of some essential oils against lice and flies infesting water buffaloes in Egypt. Vet. Parasitol., 164: 257-266. doi:10.1016/j.vetpar.
- Khater HF, Hanafy A, Abdel-Mageed AD, Ramadan MY, El-Madawy RS (2011). The insecticidal effect of some Egyptian plant oils against *Lucilia sericata* (Diptera: Calliphoridae). Intern. J. Dermatol., 50: 187-194.
- Kim KS, Lee S, Jung SH, Shin KH, Kim BK (2003). Anti-oxidant activities of the extracts from the herbs of *Artemisia apiacea*. J. Ethnopharmacol., 85: 69-72.
- Kosalge S, Fursule R (2009). Investigation of *in vitro* anthelmintic activity of the *Spesial lampas* (CAV). Asian J. Pharm. Clin. Res., 2:69-71.
- Laid M, Hegazy MEF, Ahmed AA (2008). Sesquiterpene lactones from Algerian *Artemisia herba alba*. Phytochem. Lett., 1: 85-88.
- Lal J, Chandra S, Raviprakash V, Sabir M (1976). *In vitro* anthelmintic action of some indigenous medicinal plants on *Ascaridia galli* worms. Indian J. Physiol. Pharmacol., 20, 64-68.
- Le Floch E (1983). Contribution to ethnobotanical study Flora of Tunisia. Flora and Vegetation Program Tunisia. Min. In the. Sup. Rech. Sci., p. 387.
- Long PL, Current WL, Noblet GP (1987). Parasites of the Christmas Turkey. Parasitol. Today, 3: 360-366.
- Lund EE, Chute AM (1972). Reciprocal responses of eight species of galliform birds and three parasites: *Heterakis gallinarum*, *Histomonas meleagridis*, and *Parahistomonas wenrichi*. J. Parasitol., 58: 940-945.
- Mali RG, Mahajan SG, Mehta AA (2007). *In vitro* screening of *Cleome viscosa*. extract for anthelmintic activity. Pharm. Biol., 45: 766-768.
- Marrif HI, Ali BH, Hassan KM (1995). Some pharmacological studies on *Artemisia herba alba* (Asso.) in rabbits and mice. J. Ethnopharmacol., 49: 51-55.
- McDougald LR (2005). Blackhead Disease (Histomoniasis) in Poultry: A Critical Review. Avian Dis. 49: 462-476. doi: 10.1637/7420-081005R.1.
- McKellar QA (1997). Ecotoxicology and residues of anthelmintic compounds. Vet. Parasitol., 72: 413-435.
- Menezes RC, Tortelly R, Gomes DC, Pinto RM (2003). Nodular thyphlitis associated with the nematodes *Heterakis gallinarum* and *Heterakis isolonche* in pheasants: frequency and pathology with evidence of neoplasia. Mem. Inst. Oswaldo Cruz, 98: 1011- 1016.
- Mobarak MG, Seddiek ShA, Soliman AS, Mobarak AA (2008). The Effect of *Artemisia* on Chickens Fed Ration Contaminated With Aflatoxin-B1. Mansura Vet. Med. J., 10: 1-13.
- Mohamed AEH, El-Sayed MA, Hegazy ME, Helaly SE, Esmail AM, Mohamed NS (2010). Chemical constituents and biological activities of *Artemisia herba-alba*. Rec. Nat. Prod., 4: 1-25.
- Movsessian SO, Pkhrikian LV (1994). Reciprocal infection of quails and hens with the nematodes *Ascaridia galli* (Schrank, 1788) and *Heterakis gallinae* single and mixed infections. Parasitol. Hung., 27: 83-85.
- Nagaich SS (2000). Studies on the anti-helmintic activity of *Allium sativum* (garlic) oil on common poultry worms *Ascaridia galli* and *Heterakis*. J. Parasitol. App. Anim. Biol., 9: 47-52.
- Naidoo V, McGawa LJ, Bisschop SPR, Duncan N, Eloff JN (2008). The value of plant extracts with antioxidant activity in attenuating coccidiosis in broiler chickens. Vet. Parasitol., 153: 214-219.
- Oliver WT (1953). Studies in phenothiazine. 1. Some *in vitro* effects of phenothiazine on *Heterakis gallinae*. Canadian J. Comp. Med., 17: 435-447.
- Papini R, Cacciuotolo E (2008). Observations on the occurrence of *Heterakis gallinarum* in laying hens kept on soil. Ital. J. Anim. Sci., 7: 487-493.
- Parida S, Patro1 VJ, Mishra US, Mohapatra L, Sannigrahi S (2010). Anthelmintic potential of crude extracts and its various fractions of different parts of *pterosperrum acerifolium* linn. Intern. J. Pharm. Sci. Rev. Res., 1: 107- 111.
- Permin A (2003). Blackhead en klassisk fjerkraesygdrom vender tilbage. Dansk Vet. Tidsskr., 86: 6-8.
- Permin A, Hansen JW (1998). Epidemiology, diagnosis and control of poultry parasites. Rome, Italy: Food and Agriculture Organization, pp. 74-105.
- Permin A, Pearman M, Nansen P, Bisgaard M, Frandsen F (1997). An investigation on different media for embryonation of *Ascaridia galli* eggs. Helminthol., 34: 75-79.
- Rachkovskaia IV (1978). Micromorphological study of the skin-muscular sac of the nematode *Ascaridia galli* exposed to anthelmintic compounds. Parazitologija, 12: 434-438.
- Reitman S, Frankel S (1957). Transaminases in serum. Am. J. Clin. Path., 28: 56.
- Reynolds JEF, Prasad AB (1982). Martindale the Extra Pharmacopoeia, 28th ed. The Pharmaceutical Press, London.
- Roberts LS, Janovy JRJ (2005) Foundation of Parasitology, 7th ed. McGraw Hill, New York, p. 702.
- Saleh MA, Belal MH, El-Baroty G (2006). Fungicidal activity of *Artemisia herba alba* Asso (Asteraceae). J. Environ. Sci. Health B., 41: 237 - 244. DOI: 10.1080/03601230500354774.
- Seddiek SHA, Mobarak MA, Mobarak AA (2007). The effect of *Artemisia herba alba* on chickens infested with *Ascaridia galli* in comparison with piperazine citrate. Mansura Vet. Med. J., 9: 165-178.
- Shalaby AA, Khater HF (2005). Toxicity of certain solvent extracts of *Rosmarinus officinalis* against *Culex pipiens* larvae. J. Egypt. Ger. Soc. Zool. 48E: pp. 69-80.
- Shivkumar YM, Kumar VL (2003). Anthelmintic activity of latex of *Calotropis procera*. Pharmaceutical Biology. Pharmaceut. Biol., 41: 263-265.
- Snedecor GW, Cochran WG (1969). Statistical methods, sixth Ed., Iowa State University Press, Ames, Iowa, USA.
- Soliman MMM (2006). Phytochemical and toxicological studies of *Artemisia* L. (Compositae) essential oil against some insect pests. Acta phytopathol. Entomol. Hung., 41: 395-406.
- Soliman MMM (2007). Phytochemical and toxicological studies of *Artemisia* L. (Compositae) essential oil against some insect pests. Arch. Phytopathology Plant Protect., 40: 128-138.
- Sollman T (1957). A manual of Pharmacology and its Application to Therapeutics and Toxicology, 8th edit. W.B Saunders Company, Philadelphia.
- Soulsby EJJ (1982). Helminths, arthropods and protozoa of domesticated animals, 7th ed. Lea and Febiger, Philadelphia.
- Steinberger E, Hänsel R, (1972). Lehrbuch der Pharmacognosie (Textbook of pharmacognosy) 3. Springer Verlag, Berlin.
- Tahraoui A, El-Hilaly J, Israili ZH, Lyoussi B (2007). Ethnopharmacological survey of plants used in the traditional treatment of hypertension and diabetes in south-eastern Morocco (*Errachidia province*). J. Ethnopharmacol., 110: 105-117.
- Tani ZB, Hassani F, Khelil MA (2008). Bioefficacy of essential oils extracted from the leaves of *Rosmarinus officinalis* and *Artemisia herba-alba* towards the Bruche bean *Acanthoscelides obtectus* (Coleoptera: Bruchidae). J. Pure Appl. Microbiol., 2: 165-170.
- Tariq KA, Chishti MZ, Ahmad F, Shawl AS (2009). Anthelmintic activity of extracts of *Artemisia absinthium* against ovine nematodes. Vet. Parasitol., 160: 83-88.
- Thienpont D, Rochette F, Vanparijs OFJ (1986). Diagnosing of helminthiasis through coprological examination. 2nd ed. Janssen Research Foundation, Beerse, Belgium, p. 205.
- Tucker CA, Yazwinski TA, Reynolds L, Johnson Z, Keating M (2007). Determination of the anthelmintic efficacy of Albendazole in the treatment of chickens naturally infected with gastrointestinal helminthes. J. Appl. Poult. Res., 16: 392-396.
- Tyler VE, Brady LR, Robbers JE (1988). Pharmacognosy, 9th ed. Lea and Fabiger, Philadelphia.
- Urban J, Kokoska L, Langrova I, Matejkova J (2008). *In vitro* anthelmintic effects of medicinal plants used in Czech Republic. Pharmaceutical Biology. Pharmaceut. Biol., 46: 808-813.
- Walter PJ, Prichard KK (1985). Chemotherapy of parasitic infections In: Campbell WC, Rew LS (eds.), Plenum, New York, pp. 278-539.
- Weichselbaum PE (1946). Colorimetric determination of total protein. Am. J. Clin. Path. 16: 40-47.

- World Health Organization (2005). Strategic orientation paper on prevention and control of malaria, Roll Back Malaria Depart., www.who.int/malaria/docs/trainingcourses/NPOreport.pdf.
- Yashphe J, Segal R, Breuer A, Erdreich-Naftali G (1979). Antibacterial activity of *Artemisia herba alba*. J. Pharm. Sci., 68: 924-925.
- Yazwinski TA, Chapman, HD, Davis RB, Letonja T, Pote L, Maes L, Vercruyse J, Jacobs DE (2003). WAAVP guidelines for evaluating the effectiveness of anthelmintics in chickens and turkeys. Vet. Parasitol., 116: 159-173.
- Zeggwagh NA, Farid O, Michel JB, Eddouks M, Moulay I (2008). Cardiovascular effect of *Artemisia herba-alba* aqueous extract in spontaneously hypertensive rats. Meth. Find. Exp. Clin. Pharmacol., 30: 375-81.
- Ziyyat A, Legssyer A, Mekhfi H, Dassouli A, Serhrouchni M, Benjelloun W (1997). Phytotherapy of hypertension and diabetes in oriental Morocco. J. Ethnopharmacol., 58: 45-54.