

Full Length Research Paper

Levels of matrix metalloproteinases (MMPs) in tear fluid of mustard gas exposed patients with chronic dry-eye symptoms

Reza Haji Hosseini* and Malek Ashtar Esfandiary

Biology Department, Payame Noor University, P. O. Box 19395-3697, Tehran, Iran.

Accepted 14 March, 2012

The purpose of this study is to compare the levels of MMP-1, 2, 8, 9 in tear fluids of people exposed to mustard gas in the war between Iraq and Iran who had the chronic dry-eye symptoms compared to the normal group. In this study, 25 of the patients who were exposed to mustard gas and had chronic dry eye symptoms were compared to 25 patients as control group; consisting of 25 people who had common chronic dry eye symptoms with blepharitis and 25 healthy people as normal group. The level of MMP-1, 2, 8, 9 in tear fluid of people of these three groups was assessed by enzyme-linked immunosorbent assay (ELISA). The results for levels of MMP-1 ($P=0.8$) and MMP-2 ($P=0.54$) in tear fluid of patients in comparison with normal group do not indicate any significant difference. On the other hand, the calculated levels for MMP-8 ($P=0.002$) and MMP-9 ($P=0.01$) in tear fluid of patients in comparison with normal group shows a significant increase. The differences were considered statistically significant at $p < 0.05$. The effects of exposure to mustard gas on eyes of chemical-injured veterans destroy meibomian glands which paves the way for evaporative dry-eye. As a result, MMPs in tear fluid of these patients increase which eventually elevates the matrix metalloproteinases (MMPs) levels in tear fluid and results in later eye-impairments.

Key words: Mustard gas, matrix metalloproteinases (MMPs), enzyme-linked immunosorbent assay (ELISA).

INTRODUCTION

Mustard gas (bis(2-chloroethyl)sulphide) was first integrated in 1822 during the studies of interactions between olefins and sulfur halogen compounds (Niemann, 1860; Guthrie, 1860). Pure sulfur mustard (SM) is a translucent, colorless liquid which is nearly odorless. Its freezing point is 14.4°C and its boiling point is between 215 and 217°C (760 mmHg). SM is the vesicant with the highest military significance. Its last military use was in the Iran-Iraq war (Goodman et al., 1984). Over 100,000 Iranians were injured by this agent and one-third is suffering from late effects until today (United Nation Security Council, 1998). After absorption, sulfur mustard attaches to active biological compounds and causes severe electrophilic tissue reactions through

developing a means of carbonium ions and momentary complexes with large molecules.

Various biochemical reactions and alterations in DNA structure can explain cytotoxic and mutagenic properties of sulfur mustard. It affects various organs such as the skin, eyes and lungs, as well as the hematological, gastrointestinal, endocrine, neuromuscular and immune system (Marrs et al., 1996). The toxicity of sulfur mustard as an incapacitating mediator is of much greater significance than its potential to cause lethality. As a matter, compared with the nerve agents, sulfur mustard has a rather low severe fatal toxicity (Maynard, 1995). Amid the survivors of mustard gas attacks in World War I and in the Iran-Iraq War, virtually all victims went through skin and eye burns and respiratory injuries (Balali and Navaeian, 1986). However, reported fatality rates were less than 2% in the exposed veterans during World War I, and 3 to 4% in the victims of the Iran-Iraq war (Maynard et al., 1991).

*Corresponding author. E-mail: hosseini@pnu.ac.ir. Tel: +98 21 22458309. Fax: +98 21 22458315.

Early toxic effects of SM on eyes

Eyes are the most vulnerable organs to sulfur mustard (Papirmeister et al., 1991). The first clinical indications strike about 1 h after exposure, starting with a feeling of grittiness, progressive tenderness and a blood-shot eye symptom, and then proceeding to edema and all the signs of acute conjunctivitis. At 2 to 6 h after exposure, patients complain of severe ocular pain, lacrimation, photophobia, and sometimes even short-term blindness. Physical findings include blepharospasm, periorbital edema, conjunctival injection, and inflammation of the anterior chamber (Solberg et al., 1997; Dahl et al., 1985).

Whereas concentrations of less than 50 mg/min/m³ instigate simple conjunctivitis, corneal inflammation and edema take place with doses above 200 mg/min/m³ (Geeraets et al., 1977). After quite a few hours, the corneal epithelium initiates to vesicate and slough, leading to regression in visual acuity. At even elevated doses, corneal ulceration may happen, with considerable visual impairment and the risk of irreversible blindness (Dahl et al., 1985). Gradual spontaneous healing usually occurs after 48 h of agonizing pain and blepharospasm, with complete regeneration of the corneal epithelium appearing within 4 to 5 days. Full symptomatic recovery may take 6 weeks or longer (Mann et al., 1948).

Late toxic effects of SM on eyes

Dry eye is a prevalent complication in these patients (Ghasemi et al., 2009). In less than 1% of patients with battlefield exposure to sulfur mustard, a delayed type of ulcerative keratopathy may develop, leading to late-arrival of blindness (Blodi, 1971; Pleyer et al., 1999). In acute stages, the limbal region recurrently presents a marbled manifestation in which porcelain-like areas of ischemia are surrounded by blood vessels of abnormal diameter. Afterward, vascularized scars of the cornea are covered with crystal and cholesterol deposits, resulting in worsening of opacification, frequent ulcerations, and sometimes corneal perforation. Opacification of the cornea is seen mainly in the lower and central sections, while the upper part is often protected by the eyelid (Solberg et al., 1997). Surprisingly, lesions even recur after corneal transplantation (Javadi, 2000).

In recent years, many studies of biochemical changes occurring in tears have been published, showed that a correlation between tear metalloproteinase (MMP) content and clinical evidence of disease progression (Smith et al., 2001). There are some result which reported that inflammatory cytokines such as interleukin(IL) 1 β and tumor necrosis factor (TNF) α which can be derived from the ocular surface and tears, maybe responsible for the increased expression MMPs in conjunctivochalasis fibroblasts (Meller et al., 2000). This suggests that ocular inflammation might be one important denominator in the pathogenesis of conjunctivochalasis

(Meller et al., 2000). The study of the expression of the Pro and anti-inflammatory forms of IL-1 in the tear and conjunctival epithelium of normal eyes and those with dry-eye disease have been published, and it had been concluded that dry-eye disease being accompanied by increasing the pro-inflammatory forms of IL-1 (IL-1 and mature IL-1 β) which can stimulate the production of MMP enzymes (Solomon et al., 2001; Matsumoto et al., 2005; Cayphas et al., 1987).

There is much evidence to suggest that MMPs play a vital role in several physiological and pathological processes. They participate in extracellular matrix (ECM) remodeling after wounding of the corner surface and have been implicated in the pathogenesis of the sterile corner of ulceration, dry-eye and other ocular diseases (Li et al., 2003). Gelatinase B (MMP-9) and gelatinase A (MMP-2) are the primary matrix-degrading enzymes produced by the corneal epithelium and fibroblasts. MMP-9 has been found to be of central importance in catalyzing the cleavage of epithelial basement membrane components ("inflammatory markers in tears of patients") (Matubara et al., 1991; Fukuda et al., 2006). To avoid excessive proteolysis and tissue damage, the proteolytic activities are highly regulated in a precise and coordinated manner through different processes such as:

- (1) Regulation of proteinases transcription and translation by growth factors or cytokines, cell-ECM or cell-cell contacts, and oncogene expression;
- (2) Proteolytic activity inhibition by their natural inhibitors, the tissue inhibitors of metalloproteinases (TIMPs). Besides their MMP inhibitory activity, TIMPs exhibit other various biological activities (Woessner, 1991; Werb et al., 1996).

The aim of the present work is to determine the concentration of MMP-1, 2, 8, 9 in the tears of patients with dry-eye disease employing the enzyme-linked immunosorbent assay (ELISA).

METHODOLOGY

Ethical approval (Appendix) was sought and approved by the Ethical Committee of the Faculty/Institute Research Committee, Payame Noor University. This study is performed in Baqiyatallah Hospital, Tehran, Iran, in 2009. Our community contains 75 men including three groups; Group 1 containing 25 healthy subjects as normal group (Mean age 53.80 \pm 4.10), Group 2 including 25 patients with common dry-eye accompanied by blepharitis as control group (Mean age 55.44 \pm 4.17), Group 3 includes 25 patients who were last exposed at least 20 years ago and had chronic dry-eye with blepharitis as patient group (Mean age 53.6 \pm 4.56 years) with P<0.05 between the ages of three groups.

Inclusion criteria

The shared inclusion criteria for all groups were being male gender, and having almost the same age range and availability for future evaluation. For Group 2, all cases had dry-eye accompanied with

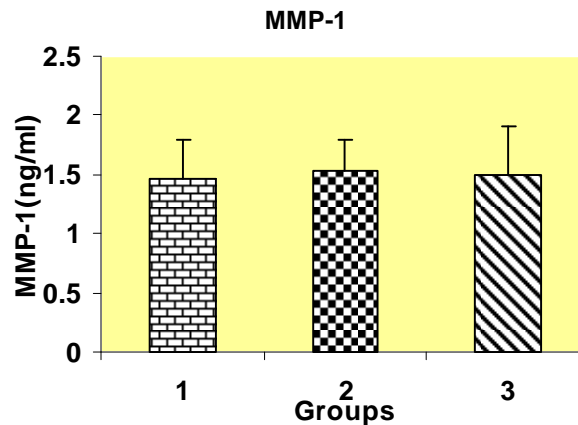


Figure 1. The mean levels of MMP-1 in tear samples. Group 1 (normal group), Group 2 (control group; common dry-eye common dry-eye accompanied by blepharitis) and Group 3 (chemical exposed veterans).

blepharitis. For group three being a chemical exposed veteran who was last exposed at least 20 years ago, and having established SM-resulted in dry-eye (according to previous medical documents) accompanied with blepharitis were the inclusion factors. Besides that all groups were examined by an ophthalmologist to be diagnosed with dry-eye and blepharitis.

Exclusion criteria

For either control or patient group any signs of infectious diseases, Sjögren's syndrome and Rheumatoid arthritis and other ocular surface diseases were our exclusion criteria.

Tear collection

Tear fluid was collected from the inferior tear meniscus, causing the least irritation possible, using a pre-weighed surgical sponges. Sponges were then placed into the end of a micropipette tip located within a 0.5 ml tube and the tear fluid was subsequently recovered by centrifugation at 8000xg at 4°C for 15 min. The tears used for protein quantification were immediately placed on ice < 1 h before freezing and storage at -80°C until they were used for enzyme-linked immunosorbent assay (ELISA) (Arantxa et al., 2008).

Enzyme –linked immunosorbent assay

The tear samples were collected to measure the levels of pro-inflammatory molecules which were obtained from different patients with the same pathologies, but we used one ELISA kit per molecule. Double sandwich ELISAs for human MMP2, 8, 9 were performed with commercial kits (Ray Biotech, Germany) according to manufacturer's protocol.

Assay procedure

All reagents and samples were brought to room temperature (18 to 25°C) before use. It is recommended that all standards and samples be run at least in duplicate. 100 µl volume of each standard and sample was added into appropriate wells. The wells

were covered and incubated for 2.5 h at room temperature or overnight at 4°C with gentle shaking. The solution was discarded and washed 4 times with wash solution. Washing was done by filling each well with wash buffer (300 µl) using a multi-channel pipette or auto-washer. Complete removal of liquid at each step is essential to good performance. After the last wash, any remaining wash buffer was removed by aspirating or decanting. The plate and blot were inverted against clean paper towels.

After that, 100 µl of 1x prepared biotinylated antibody (Reagent preparation step 6) were added to each well, incubated for 1 h at room temperature with gentle shaking and the solution was discarded. The wash was repeated as in step 3. Later, 100 µl of prepared Streptavidin solution was added to each well, incubated for 45 min at room temperature with gentle shaking and the solution was discarded and the wash repeated again as in step 3. Then, 100 µl of TMB one-step substrate reagent was added (Item H) to each well. The solution was incubated for 30 min at room temperature in the dark with gentle shaking. In the end, 50 µl of stop solution (Item I) was added to each well and read at 450 nm immediately.

Statistical analysis

The Mann-Whitney U test was used for statistical comparisons between groups. Data are expressed as means±SD and the differences were considered statistically significant at $P < 0.05$.

RESULTS

In this study, the mean levels of MMP-1, 2, 8, 9 in tear fluid of three pre-defined groups have been calculated and represented in Figures 1 to 4. The mean levels of MMP-1 in tear fluid of Group 1, chemical exposed veterans, (1.5 ± 0.41 ng/ml; $P=0.8$), and in Group 2, control group, (1.53 ± 0.27 ng/ml; $P=0.1$) were calculated and were not significant in comparison with Group 1, normal control (1.46 ± 0.34 ng/ml) (Figure 1). Also, there were no significant differences in levels of MMP-2 in tear fluid of Group 3 (18.64 ± 4.48 ng/ml; $P=0.55$) and Group 2

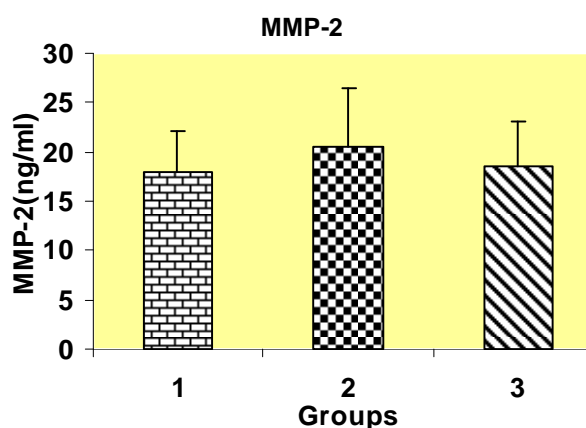


Figure 2. The mean levels of MMP-2 in tear samples. Group 1 (normal group), Group 2 (control group; common dry-eye accompanied by blepharitis) and Group 3 (chemical exposed veterans).

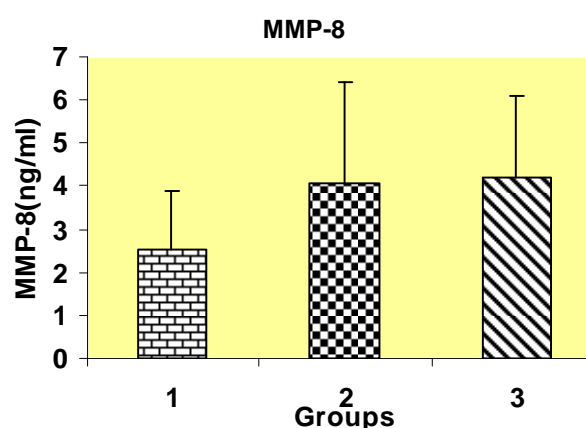


Figure 3. The mean levels of MMP-8 in tear samples. Group 1 (normal group), Group 2 (control group; common dry-eye accompanied by blepharitis), and Group 3 (chemical exposed veterans).

(20.56 ± 5.8 ng/ml; $P=0.25$) compared to Group 1 (17.96 ± 4.14 ng/ml) (Figure 2).

Nonetheless, the mean levels of MMP-8 in tear fluid of Group 3 (4.2 ± 1.91 ng/ml; $P=0.002$) and in Group 2 (4.06 ± 2.34 ng/ml; $P=0.02$) were significantly higher in comparison with Group 1 (2.51 ± 1.37 ng/ml) (Figure 3). Furthermore, mean concentrations of MMP-9 in tear fluid of Group 3 (2162 ± 1388 ng/ml; $P=0.001$) and in Group 2 (1971 ± 1292 ng/ml; $P=0.01$) were calculated which indicate a significant difference in comparison with Group 1 (977 ± 1092 ng/ml) (Figure 4).

DISCUSSION

Dry eye is one of the late outcomes of being exposed to

mustard gas, which the chemically injured veterans of Iran-Iraq war are suffering from. Also, dry eye is one of the most important factors in eye injuries in these people. Dry eye in chemical veterans has several reasons of which meibomian gland damages as a result of exposure to mustard gas manifested as posterior blepharitis, is one of the fundamental reasons (Ghasemi et al., 2009). As a result of meibomian glands damage (MGD) lipid layer production is being impeded and consequently the amount of bipolar lipids especially sphingomyelin in tear fluid is reduced dramatically (McCully and Shine, 1997, 2002), which in turn results in inflammatory stimulation of conjunctiva and generates the evaporative form of dry eye. Evaporative form of dry eye which is also observed in blepharitis is possibly the main agent for increase in concentration of enzymes responsible for extracellular

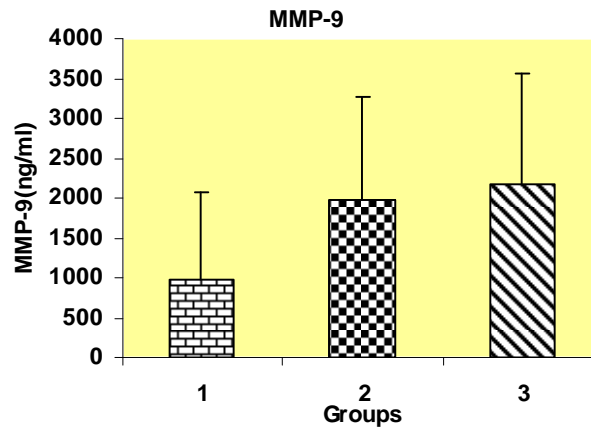


Figure 4. The mean levels of MMP-9 in tear samples. Group 1 (normal group), Group 2 (control group; common dry-eye common dry-eye accompanied by blepharitis) and Group 3 (chemical exposed veterans).

matrix breakup (matrix metalloproteinase) in tear fluid (Mathers, 1993).

Matrix metalloproteinase aggregation in tear fluid damages the corneal epithelial membrane as disassembles the collagens and mainly stromatal matter of cornea and results in serious damage in the cornea (Afonso et al., 1999). In a study performed by Arantxa, the increasing amount of proMMP-9 on patients with blepharitis has been reported (Arantxa et al., 2008). In this study which was performed on 25 patients suffering from blepharitis (Group 2) the amount of MMP-9 in tear fluid of these people shows a significant increase in comparison with the normal group ($P=0.01$). Also, the results taken out of ELISA shows a significant increase in MMP-9 levels in tear fluid of chemically injured veterans against the normal group ($P=0.001$). MMP-9 (gelatinase B) is secreted by corneal epithelium cells (tear fluid) in eye and has a crucial role in degradation of amorphous collagens gelatinases (Matsubara et al., 1991).

In normal tear fluid, there is a certain amount of MMP-9 which has a fundamental role in healing and recovering in corneal injuries (tear fluid) and with inordinate increase of matrix metalloproteinases in tear, it causes destruction of corneal epithelium membrane and eventually corneal injury. Studies show that MMP-8 in tear fluid of patients suffering from OCR is significantly high (Maatta et al., 2006). The OCR is a disease accompanied with eyelid marginal telangiectasia and inflammation of meibomian glands which normally causes dry eye (Quarterman et al., 1997). In our study, the amounts of MMP-8 in tear fluid of people with posterior blepharitis shows a significant increase in comparison with the normal group ($P=0.02$). Also, the results of our research shows that the amount of MMP-8 in tear fluid of chemically injured veterans exposed to mustard gas indicates a significant difference compared to normal people ($P=0.002$).

Normal tear fluid has a certain amount of MMP-8(type 2

collagenase) (Kiili et al., 2002). This enzyme has high capabilities for breaking type II and III collagens (Matsuki et al., 1996). As a matter of fact, MMP-8 is more effective on type I collagen which is the main collagen in cornea. Inordinate increase of this matrix metalloproteinase in tear fluid can have a significant role in degradation of type I collagens and destruction of cornea (Maatta et al., 2006). In the present study, the results given by ELISA showed that the levels of MMP-1, 2 in tear fluid of patients suffering from posterior blepharitis (Group 2) did not explore a significant difference with regard to the normal group. Other studies showed that the levels of MMP-1, 2 in tear fluid of chemically-injured veterans who were exposed to mustard gas (Group 3) did not show any significant difference in relation to the normal group. One of the reasons which was proposed for MMPs increase in tear fluid of patients with blepharitis is the evaporative form of dry eye in these patients which results in accumulation of these enzymes (MMPs) in tear fluid (McCully and Shine, 1997) and initiates other injuries in eyes. Besides this theory, it can be also applied to chemically-injured veterans, whose meibomian glands injured and pave the way for chronic blepharitis.

On the other hand, escalated levels of MMP-8, 9 in tear fluid of these veterans perhaps is as a result of mutagenic and destructive effects of SM respectively on DNA (Ludlum et al., 1994, 1984, 1986; Niu et al., 1996; Lawley et al., 1969; Smith et al., 1993; Rosenthal et al., 1998) and epithelial cells of cornea which is followed by over-expression of genes responsible for MMP-8,9 or under-expression of their inhibitors (TIMPs) in corneal epithelial cells. So for further research, it is worth designing some experiments to assert this theory. In addition, since MMP-9 accounts for an inflammatory factor (Arantxa et al., 2008) therefore the elevated levels of MMP-9 in tear fluid of these chemical veterans who were exposed to mustard gas, may be because of a kind

of inflammatory process in their eyes which is still active in their eyes, 20 years after exposure. This fact can be studied by measuring other inflammatory factors such as IL- α , IL-6, IL-8 and TNF- α , which stimulate the production of MMPs in tear fluid of these chemical veterans (Solomon et al., 2001; Matsumoto et al., 2005; Cayphas et al., 1987).

REFERENCES

- Afonso AA, Sobrin L, Monroy DC, Selzer M, Lokeshwar B, Pflugfelder SC (1999). Tear fluid gelatinase B activity correlates with IL-1 α concentration and fluorescein clearance in ocular rosacea. *Invest. Ophthalmol. Vis. Sci.*, 40: 2506-2512.
- Arantxa A, Germán R, Elena V, Isabel L, Juan A (2008). Durán. Inflammatory Markers in the Tears of Patients with Ocular Surface Disease. *Ophthalmic Res.*, 40: 315-321.
- Balali M, Navaeian A (1986). Clinical and paraclinical findings in 233 patients with sulfur mustard poisoning. In: Proceedings of the second world congress on new compounds in biological and chemical warfare: toxicological evaluation. Ed.: B. Heyndrickx. Ghent University Press, Ghent, Belgium: pp. 464-473.
- Blodi FC (1971). Mustard gas keratopathy. *Int. Ophthalmol. Clin.*, 2: 1-13.
- Cayphas S, Van Damme J, Vink A, Simpson RJ, Billiau A, Van Snick J (1987). Identification of an interleukin HPI-like plasmacytoma growth factor produced by L cells in response to viral infection. *J. Immunol.*, 139: 2965-2965.
- Dahl H, Gluud B, Vangsted P, Norn M (1985). Eye lesions induced by mustard gas. *Acta Ophthalmol.*, 173 (suppl.): S30-S81.
- Fukuda K, Fujitsu Y, Kumagai N, Nishida T (2006). Inhibition of matrix metalloproteinase-3 in human conjunctival fibroblasts by interleukin-4 or interleukin-13. *Invest. Ophthalmol. Vis. Sci.*, 47: 2857-2864.
- Geeraets WJ, Abedi S, Blank RV (1977). Acute corneal injury by mustard gas. *South. Med. J.*, 70: 348-351.
- Ghasemi H, Ghazanfari T, Ghassemi-Broumand M, Javadi MA, Babaei M, Soroush MR, Yaraee R, Faghihzadeh S, Poorfarzam S, Owlia P, Naghizadeh MM, Etezzad-Razavi M, Jadidi K, Naderi M, Hassan ZM (2009). Long-term ocular consequences of sulfur mustard in seriously eye-injured war veterans. *Cutan. Ocul. Toxicol.*, 28(2): 71-7.
- Goodman LS, Wintrobe MM, Dameshek W, Goodman MJ, Gilman A, McLennan, MT (1984). Nitrogen mustard therapy. Use of methyl-bis(beta-chloroethyl)amine hydrochloride and tris(beta-chloroethyl)amine hydrochloride for Hodgkin's disease, lymphosarcoma, leukemia and certain allied and miscellaneous disorders. *JAMA*, 251: 2255-2261.
- Guthrie F (1860). On certain derivatives of hydrocarbons CnHn. *Ann. Chem. Pharm.*, pp. 266-288.
- Javadi MA (2000). Prevention and treatment of complications of CWA. *Chem. Warf. Victims Res. Centre, Tehran*. pp. 81-101.
- Kiili M, Cox SW, Chen HY, Whalgren J, Maisi P, Eley BM, Salo T, Sorsa T (2002). Collagenase-2 (MMP-8) and collagenase-3 (MMP-13) in adult periodontitis: molecular forms and levels in gingival crevicular fluid and immunolocalisation in gingival tissue. *J. Clin. Periodontol.*, 29: 224-232.
- Lawley PD, Lethbridge JH, Edwards PA, Shooter KV (1969). Inactivation of bacteriophage τ by mono- and difunctional sulfur mustards in relation to cross-linking and depurination of bacteriophage DNA. *J. Mol. Biol.*, 39: 181-198.
- Li DQ, Shang TY, Kim H, Solomon A, Lokeshwar BL, Pflugfelder SC (2003). Regulated expression of collagenases MMP-1, -8, and -13 and stromelysins MMP-3, -10, and -11 by human corneal epithelial cells. *Invest. Ophthalmol. Vis. Sci.*, 44: 2928-2936.
- Ludlum DB, Kent S, Mehta JR (1986). Formation of O6-ethylthioethylguanine in DNA by reaction with the sulfur mustard, chloroethyl sulfide, and its apparent lack of repair by O6-alkylguanine-DNA alkyltransferase. *Carcinogenesis*, 7: 1203-1206.
- Ludlum DB, Ritchie PA, Hagopian M, Niu TQ, Yu D (1994). Detection of sulfur mustard-induced DNA modifications. *Chem. Biol. Interact.*, 91: 39-49.
- Ludlum DB, Tong WP, Mehta JR, Kirk MC, Papimeister B (1984). Formation of O6-ethylthioethyldeoxyguanosine from the reaction of chloroethyl ethyl sulfide with deoxyguanosine. *Can. Res.*, 44: 5698-5701.
- Maatta M, Kari O, Tervahartiala T, Peltonen S, Kari M, Saari M, Sorsa T (2006). Tear fluid levels of MMP-8 are elevated in ocular rosacea — Treatment effect of oral doxycycline. *Graefes Arch. Clin. Exp. Ophthalmol.*, 244: 957-962.
- Mann I, Pirie A, Pullinger BD (1948). An experimental and clinical study of the reaction of the anterior segment of the eye to chemical injury, with special references to chemical warfare agents. *Brit. J. Ophthalmol. Monograph Supplement XIII*.
- Marrs TC, Maynard R L, Sidell FR (1996). Chemical warfare agents: toxicology and treatment, John Wiley and Sons, Chichester, UK.
- Mathers WD (1993). Ocular evaporation in meibomian gland dysfunction and dry eye. *Ophthalmology*, 100: 347-351.
- Matsubara M, Zieske JD, Fini ME (1991). Mechanism of basement membrane dissolution preceding corneal ulceration. *Invest. Ophthalmol. Vis. Sci.*, 32: 3221-3237.
- Matsuki H, Fujimoto N, Iwata K, Knäuper V, Okada Y, Hayakawa Y (1996). A one-step sandwich enzyme immunoassay for human matrix metalloproteinase 8 (neutrophil collagenase) using monoclonal antibodies. *Clin. Chim. Acta.*, 244: 129-143.
- Matsumoto K, Ikema K, Tanihara H (2005). Role of cytokines in pseudomonal keratitis. *Cornea*, 24: 43-49.
- Matubara M, Girard MT, Kublin CL, Cintron C, Fini ME (1991). Differential role for two gelatinolytic enzymes of the matrix metalloproteinase family in the remodeling cornea. *Dev. Biol.*, 147: 425-439.
- Maynard RL (1995). Chemical warfare agents. In: General and applied toxicology. Eds.: B. Ballantyne, T. Marrs & P. Turner. MacMillan Press Ltd: pp. 1123-1156.
- Maynard RL, Meredith TJ, Marrs TC, Vale JA (1991). Management of war injuries. *Lancet*, 337: 122.
- McCully Jp, Shine W (1997) A compositional based model for the tear film lipid layer. *Trans Am. Ophthalmol. Soc.*, 95: 79-88.
- McCully Jp, Shine W (2002). Meibomian gland and tear film lipids: structure, function and control, Lacrimal gland, tear film, and dry eye syndromes. *Adv. Exp. Med. Biol.*, 506: 373-378.
- Meller D, Li DQ, Tseng SCG (2000). Regulation of gelatinase B in human conjunctivochalasis fibroblasts by interleukine-1 β and tumor necrosis factor- α . *Invest. Ophthalmol. Vis. Sci.*, 41: 2922-2929.
- Niemann A (1860). On the effect of sulfur on chlorine brown Elaylgas. *Ann. Chem. Pharm.*, 113: 288-292.
- Niu ZM, Matijasevic Z, Ritchie PA, Stering A, Ludlum BD (1996). A 32P-postlabeling method for the detection of adducts in the DNA of human fibroblasts exposed to sulfur mustard. *Chem. Biol. Interact.*, 100: 77-84.
- Papimeister B, Feister AJ, Robinson SI, Ford RD (1991). Medical Defence against mustard gas, toxic mechanisms and pharmacological implications, CRC. Boca Raton.
- Pleyer U, Sherif Z, Baatz H, Hartmann C (1999). Delayed mustard gas keratopathy, clinical findings and confocal microscopy. *Am. J. Ophthalmol.*, 128: 506-507.
- Quarterman MJ, Johnson DW, Abele DC, Leshner JL Jr, Hull DS, Davis LS (1997). Ocular rosacea. Signs, symptoms, and tear studies before and after treatment with doxycycline. *Arch. Dermatol.*, 133: 49-54.
- Rosenthal DS, Simbulan MG, Iyer S, Spoonde A, Smith W, Ray R, Smulson EM (1998). Sulfur mustard induces markers of terminal differentiation and apoptosis in keratinocytes via a Ca²⁺-calmodulin and caspase-dependent pathway. *J. Invest. Dermatol.*, 111: 64-71.
- Smith VA, Rishmawi H, Hussein H, Easty DL (2001). Tear film MMP accumulation and corneal disease. *Br. J. Ophthalmol.*, 85: 147-153.
- Smith WJ, Sanders KM, Ruppel SE, Gross CL (1993). Cytometric analysis of DNA changes induced by sulfur mustard. *J. Toxicol. Cutaneous Ocul. Toxicol.*, 12: 337-347.
- Solberg Y, Alcalay M, Belkin M (1997). Ocular injury by mustard gas. *Surv. Ophthalmol.*, 41: 461-466.
- Solomon A, Dursun D, Liu Z, Xie Y, Macri A, Pflugfelder SC (2001). Pro-and anti-inflammatory forms of interleukin-1 in tear fluid and conjunctiva of patients with dry eye disease. *Invest. ophthalmol. Vis.*

- Sci., 42: 2283-2292.
- Werb Z, Ashkenas J, MacAuley A, Wiesen JF (1996). Extracellular matrix remodeling as a regulator of stromal-epithelial interactions during mammary gland development. *Braz. J. Med. Biol. Res.*, 29:1087-1097.
- Woessner JF Jr (1991). Matrix metalloproteinases and their inhibitors in connective tissue remodeling. *Faseb J.*, 5(8): 2145-2154.