

Full Length Research Paper

Effect of ethanol and sialidase activities on the developing kidney of Wistar rats

Wilson, J. I.^{1*}, Emonido, O. F.¹, Akpulu S. P.² and Igbigbi, P. S.¹

¹Department of Anatomy and Cell Biology, Delta State University, Abraka, Nigeria.

²Department of Human Anatomy, Ahmadu Bello University, Zaria, Kaduna State, Nigeria.

Accepted 23 August, 2011

The use of ethanol is widespread and its adverse effects have been documented. This study was to investigate the histological changes and sialic acid levels of the developing kidney as a result of oral administration of ethanol for thirty days. Twenty five adult Wistar rats, between 170 and 200 g in weight divided into five groups of five rats each were used for this study. 0.18 to 0.19 ml, 0.17 to 0.20 ml, 0.17 to 0.20 ml and 0.17 to 0.18 ml of ethanol was orally administered daily to the rats in Groups II, III, IV and V respectively and the Control group I to 0.2 ml of distilled water. The rats were sacrificed, kidneys were fixed in 10% formal saline for histological studies and others homogenised for sialic acid analysis. The results obtained show distortion of the Bowman's capsule. Karyolytic, karyorrhexic and the cells in the proximal and distal convoluted tubules were in a state of cell death for those animals exposed to ethanol, while those for the control rats appeared normal. The free, bound and total sialic acid levels of the developing kidneys showed statistically significant differences ($p < 0.05$). Ethanol consumption during pregnancy even at lower doses may lead to degenerative changes in the developing kidney.

Key words: Ethanol, karyolytic and karyorrhexic cells, tubules.

INTRODUCTION

Alcohol is a high source of energy, yielding seven calories per gram of alcohol (Puddey et al., 1985). Alcohol is often referred to as a source of empty calories, meaning that it has no nutritive value other than providing energy. This is not strictly true since some alcoholic beverages contain sugar, traces of vitamins and minerals (Cushman, 2001). These sugar and traces of vitamins do not usually make any significant contribution to the diet.

Alcohol causes damage in the developing kidney of Wistar rats, ranging from cell damage and enlargement of kidney to alcohol impacts of the various hormones that control kidney function, creating an ionic imbalance in the body that can negatively affect many metabolic processes (Ulleland, 1990). Alcohol is not digested like other foods. Instead of being converted and transported to cells and tissues, it avoids the normal digestive process and goes directly to the blood stream. About 20% of the alcohol is absorbed directly into the blood stream through the stomach walls and 80% is absorbed

into the blood stream through the small intestine.

The aims of the study are to examine the toxic effect of ethanol on the developing kidney: the histological changes during development by comparing the experimental groups with the control, and the activities of the enzyme sialidase by measuring the kidney free, bound and total sialic acid levels of the developing kidneys of Wistar rats. Ethyl alcohol or ethanol known commonly as alcohol is the same whether the beverage is wine, beer or hard liquor. Alcoholic beverage is a drug that depresses the central nervous system, like barbiturates, sedatives and anesthetics (Michaele and Ernest, 2001).

MATERIALS AND METHODS

Animals: Twenty five adult Wistar rats, between 170 and 200 g in weight were used for this study. They were divided into five groups of five Wistar rats each. Daily oral dose of 0.18 to 0.19 ml, 0.17 to 0.20 ml, 0.17 to 0.20 ml and 0.17 to 0.18 ml of ethanol was administered to the Wistar rats in Groups II (4% ethanol), III (12% ethanol), IV (30% ethanol) and V (40% ethanol) respectively (weight/ volume). The Control group I was administered with a daily oral dose of 0.2 ml of distilled water. The process of preparation of

*Corresponding author. E-mail: docwiliju@yahoo.com. Tel: +234 80 33367168.

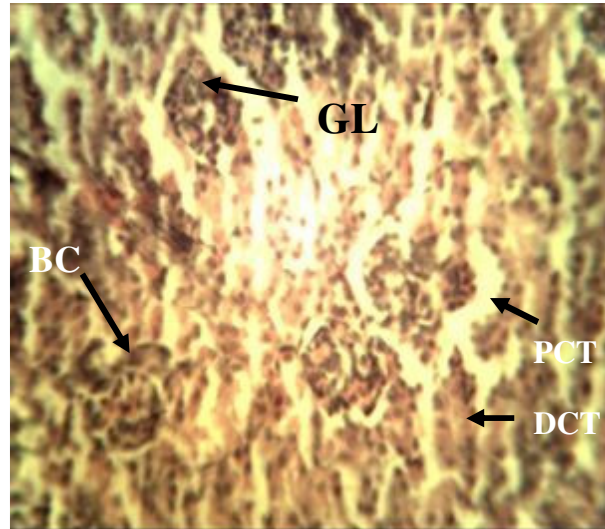


Plate 1. Coronal section of developing kidney of Wistar rat. Group I (control). H and E \times 400. Note: BC – Bowman's capsule, GL – glomerulus, PCT – proximal convoluted tubule, DCT – distal convoluted tubule.

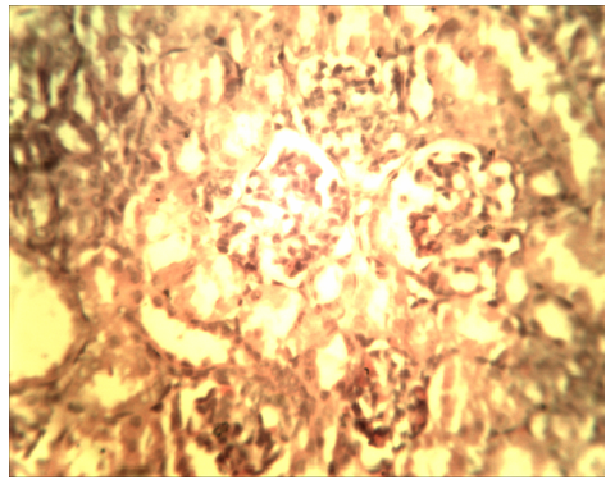


Plate 2. Coronal section of developing kidney of Wistar rat. Group II (4% Ethanol). H and E \times 400.

kidney tissue for histological examinations was separated into a number of stages. These stages included: fixation, tissue processing, sectioning, staining and mounting. The tissues were stained using routine (H and E) staining. Photomicrography was done using digital microscope eyepiece "SCOPETEK" DCM 500, 5.0 megapixel.

The litters of the Wistar rats in each group were sacrificed on postnatal day one (PND-1) by cervical dislocation and kidney tissues were carefully removed whole for histology and sialic acid analysis. 0.1 g of kidney tissues was homogenized with 1 ml of deionized water for determination of both kidney free and bound sialic acid levels using the thiobarbituric (TBA) assay according to Aminoff (1961).

RESULTS

The results obtained are shown in Plates 1 to 5 and Figures 1 to 3.

Microscopic examination of the developing kidney

Plate 1 (Group I – control) shows the intact Bowman's capsule. The glomerulus contains cells with tuft capillaries. The distal convoluted tubules show normal

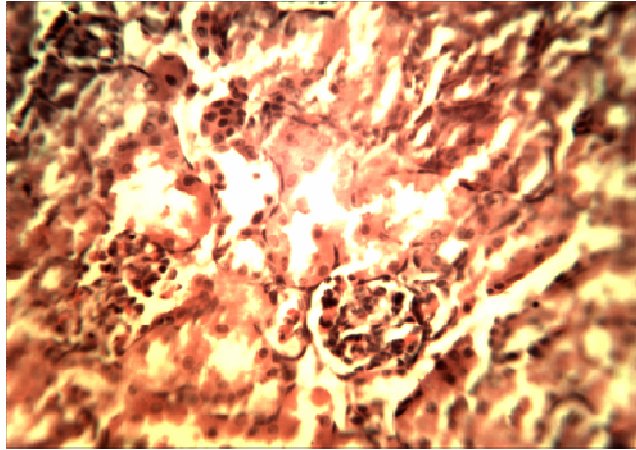


Plate 3. Coronal section of developing kidney of Wistar rat. Group III (12% ethanol). H and E \times 400.

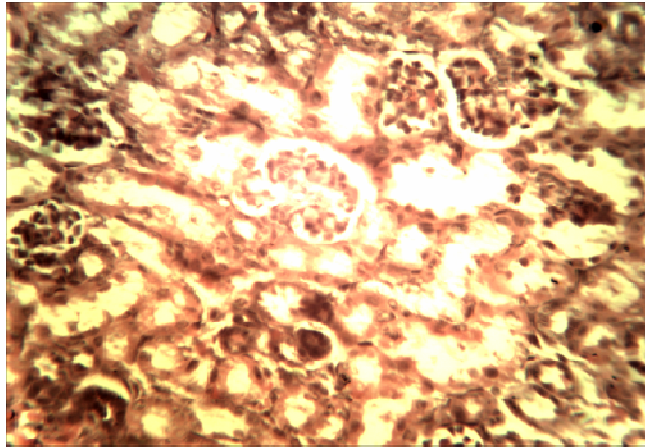


Plate 4. Coronal section of developing kidney of Wistar rat. Group IV (30% ethanol). H and E \times 400.

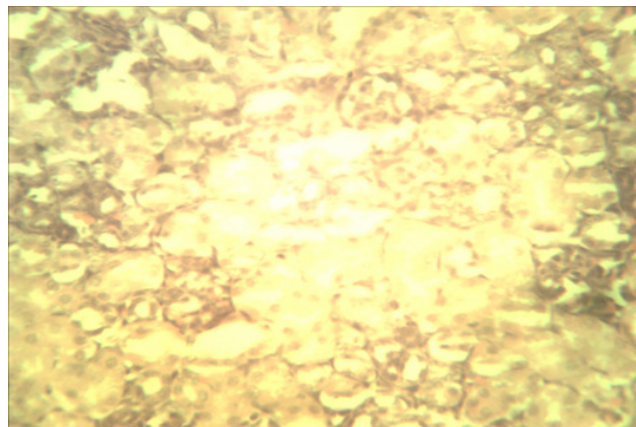


Plate 5. Coronal section of developing kidney. Group V (40% ethanol). H and E \times 400.

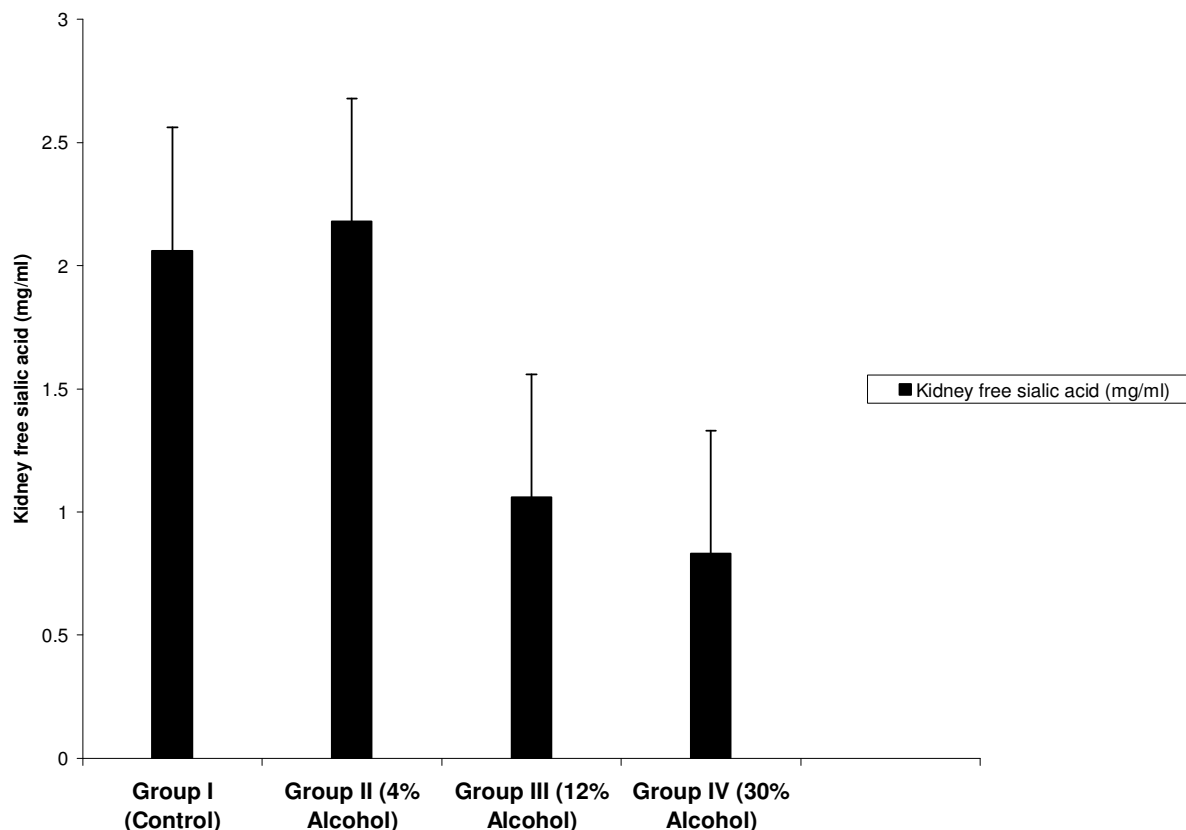


Figure 1. Developing kidney free sialic acid of Wistar rats after oral administration of ethanol for 30 days. Note: The increased activity of the enzyme sialidase is noted in Groups III to IV.

outline. The proximal convoluted tubules show single cuboidal epithelial cells with normal cellular structure.

Plate 2 (Group II – 4% ethanol) shows the distortion of Bowman's capsule architecture. The Bowman's space is seen are signs of cell death. Proximal and distal convoluted tubules are sparsely distributed.

Plate 4 (Group IV – 30% ethanol) shows the distortion of glomerulus. Proximal convoluted tubules are destroyed. In the distal convoluted tubules the cells are in a state of cell death. There are observable pyknotic, karyolytic and karyorrhexic cells.

Plate 5 (Group V – 40% ethanol) shows severe distortion of the glomerulus and Bowman's capsule. There are distortions of the proximal and distal convoluted tubules as a result of necrosis. The tissue is filled with pyknotic and karyorrhexic cells. The karyolytic cells show sign of complete dissolution of chromatin.

Kidney free sialic acid

Figure 1 show the kidney free sialic acid levels of Wistar rats. The kidney free sialic acid of Wistar rats was affected by the oral administration of ethanol. Sialic acid levels decreased in groups III, and IV (the groups that

destroyed. The glomerulus contains pyknotic, karyolytic and karyorrhexic cells.

Plate 3 (Group III – 12% ethanol) shows total distortion of the Bowman's capsule. Pyknotic and karyorrhexic cells had 12 and 30% of ethanol, respectively) when compared with the control group I that had 0% of ethanol. The mean and standard error of mean values of kidney free sialic acid as contained in Figure 1 in Groups I (control), II, III and IV are 2.058 ± 0.0796 , 2.180 ± 0.0450 , 1.055 ± 0.0629 and 0.833 ± 0.0626 respectively ($p = 0.002$). Specifically, there was statistically significant difference between Groups I and III, I and IV, II and III, II and IV ($p < 0.05$).

Kidney bound sialic acid

Figure 2 shows the kidney bound sialic acid levels of Wistar rats. The kidney bound sialic acid of Wistar rats was affected by the oral administration of ethanol. Sialic acid levels decreased in Groups II, III, and IV (the groups that had 4, 12 and 30% of ethanol, respectively) when compared with the control Group I that had 0% of ethanol. The mean and standard error of mean values of kidney bound sialic acid as contained in Figure 2 in

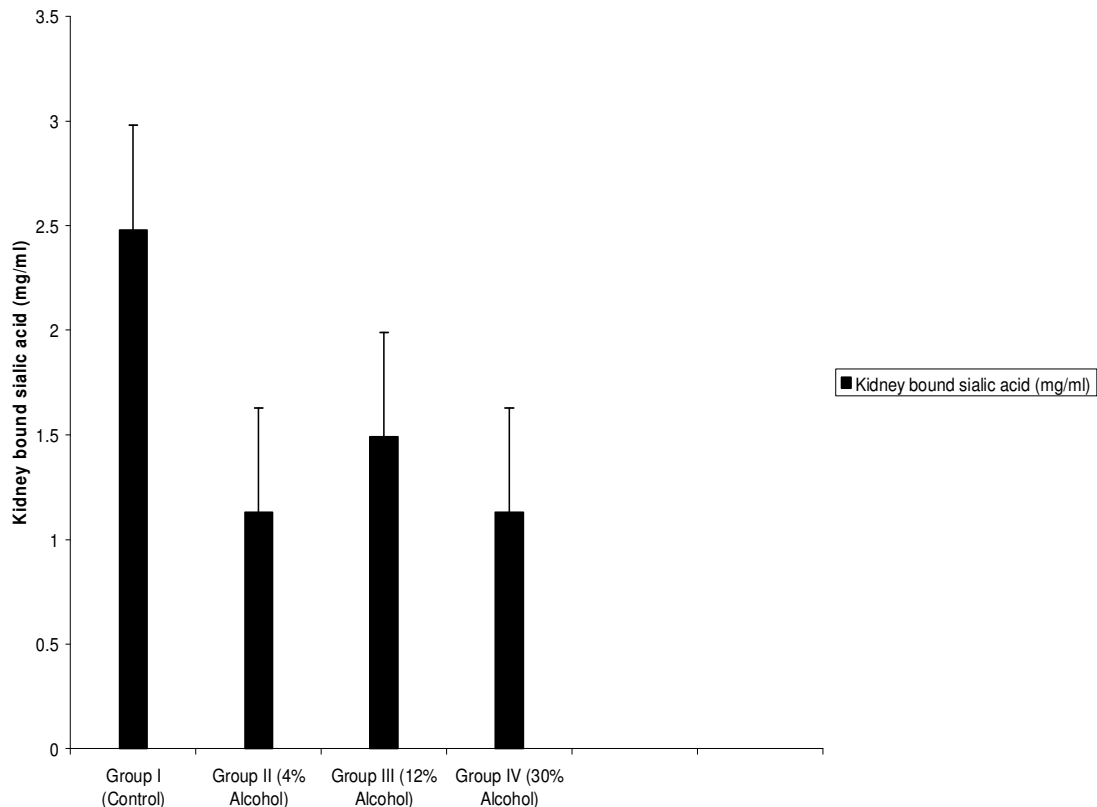


Figure 2. Developing kidney bound sialic acid of Wistar rats after oral administration of ethanol for 30 days. Note: The increased activity of the enzyme sialidase is noted in Groups II to IV.

Specifically, there was statistical significant difference between Groups I and II, I and III, I and IV ($p < 0.05$).

Kidney total sialic acid

Figure 3 shows the kidney total sialic acid levels of Wistar rats. The kidney total sialic acid of Wistar rats was affected by the oral administration of ethanol. Sialic acid levels decreased in Groups II, III, and IV (the groups that had 4, 12 and 30% of ethanol, respectively) when compared with the control Group I that had 0% of ethanol. The mean and standard error of mean values of sialic acid contained in Figure 3 in Groups I (control), II, III and IV are 4.533 ± 0.163 , 3.308 ± 0.491 , 2.547 ± 0.340 and 1.960 ± 0.242 respectively ($p < 0.001$). Specifically, there was statistical significant difference between Groups I and III, I and IV ($p < 0.05$).

DISCUSSION

The distortions of the Bowman's capsule and glomerulus, pyknotic, karyolytic and karyorrhexic cells as well as cells of the renal tubules (proximal and distal) noted show

signs of degenerative changes. These findings are in agreement with Brzoska et al. (2000), who demonstrated that there were tubular degeneration and hypertrophy of epithelial cells in the kidney of rats exposed to 10% ethanol. Assadi (2008) noted that the offspring of the alcohol exposed rats during gestation developed renal cell injury in the nephron which included cytoplasmic mitochondrial hypertrophy and vacuolar structures of the epithelial cells of the cortical collecting ducts in the rat kidney. Assadi et al. (1990) demonstrated renal tubular cell injury that may arise from direct effect of ethanol on tissues. Alcohol crosses the foetal placental barrier and rapidly reaches the foetus. Extensive studies have demonstrated equivalent foetal and maternal alcohol concentrations suggestive of an unimpeded bidirectional movement of alcohol between the two compartments (Abel, 1996; Day et al., 1991).

The cleaving of sialic acid by the enzyme sialidase may have exposed the kidney to the damage noticed. Also, we found out that the increase in the dose of the ethanol resulted in the decrease of kidney total sialic acid levels, showing a high activity of the enzyme sialidase. In this study, the kidney free, bound and total sialic acid levels showed statistically significant differences between the experimental groups ($p = 0.002$, $p < 0.001$ and $p < 0.001$).

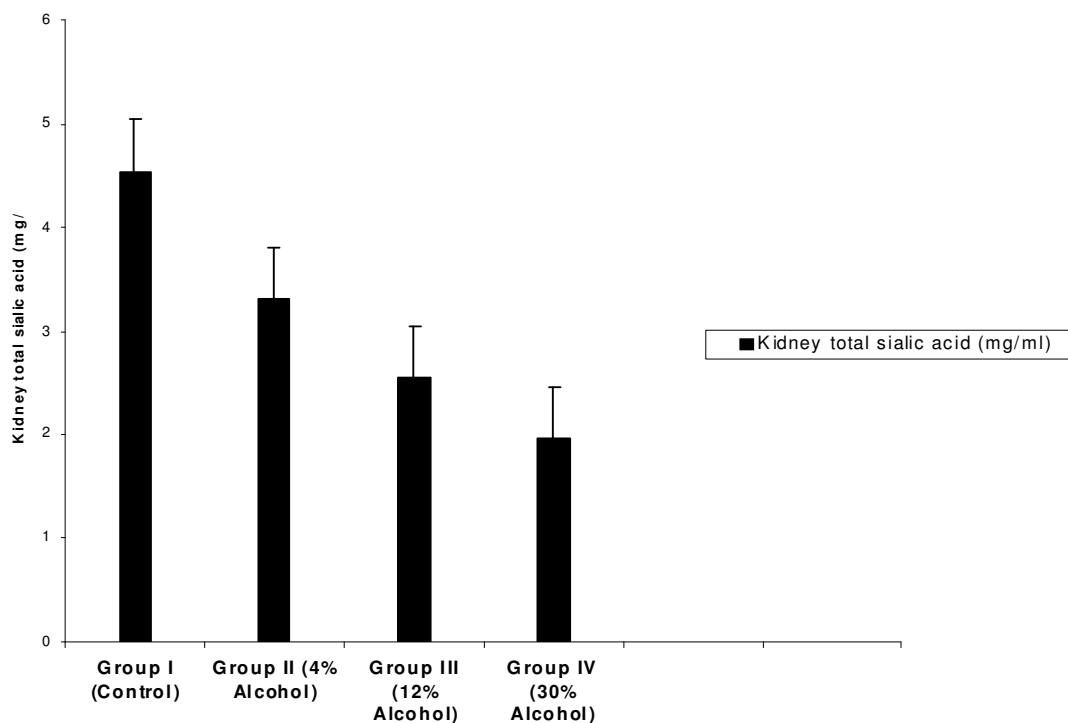


Figure 3. Developing kidney total sialic acid of Wistar rats after oral administration of ethanol for 30 days. Note: The increased activity of the enzyme sialidase is noted in Groups II to IV.

respectively. Ethanol may be teratogenic and should be avoided, especially during pregnancy. Consumption of ethanol even at lower doses (4%) may lead to degenerative changes in the development of the kidney. The damage to the kidney by ethanol was dose dependent.

ACKNOWLEDGEMENT

We thank Dr. B. Danborno and J. Timbuak for their contributions.

REFERENCES

- Abel EL (1996). Moderate drinking during pregnancy: cause for Concern? *Clinical*, 268(1-2): 149-154.
- Aminoff D (1961). Methods for the qualitative estimation of N-acetylneuraminic acid and their application to hydrolysis of sialomucoids. *Biochem. J.*, 81: 384-392.
- Assadi F (2008). Effects of Prenatal Alcohol Exposure on the Developing Kidneys. *Iran J. Pediatr.*, 18(1) pp. 5-10.
- Assadi F, Manaligod JR, Fleischmann LE (1990). Effects of Prenatal Ethanol Exposure on Postnatal Renal Function and Structure in the Rat. *Alcohol.*, 8(4): 259-263.
- Brzoska MM, Moniuszko J, Jurczuk M, Galazyn SM, Rogalska J (2000). Effect of Short term Ethanol Administration on Cadmium Retention and Bioelements Metabolism in Rat Continuously Exposed to Cadmium. *Alcohol and Alcoholism*. 35: 439-445.
- Cushman WC (2001). Alcohol Consumption and Hypertension. *J. Clin. Hypertens*, 3(3): 166-170.
- Day NL, Richardson GA (1991): Prenatal Alcohol exposure: a continuum of effect: *Perinatology*, 15 (4): 271-279.
- Michael T, Ernest C (2001). An intervention with high risk mother who abuse alcohol and drugs: the Zeattle Advocacy Model. *Am. J. Public Health*, pp. 1816-1817.