

Full Length Research Paper

The histopathologic effects of *Securidaca longepedunculata* on heart, liver, kidney and lungs of rats

Dapar, L. P. Maxwell¹*, Aguiyi, C. John¹, Wannang, N. Noel², Gyang, S. Steven² and Tanko, M. Naanlep³

¹Department of Clinical Pharmacy, Faculty of Pharmaceutical Sciences, University of Jos, Nigeria.

²Department of Pharmacology, Faculty of Pharmaceutical Sciences, University of Jos, Nigeria.

³Department of Pathology, Faculty of Medical Sciences, University of Jos, Nigeria.

Accepted 19 January, 2007

Securidaca longepedunculata is a savannah shrub commonly used by traditional medicine practitioners in Nigeria; the plant is reputed to have over one hundred medicinal indications. In this investigation, the histopathologic effects of *S. longepedunculata* on the heart, kidneys, liver and lungs of rats were examined. Albino rats (Sprague Dawley strain) weighing 200 – 250 g were given 2 mg/kg (I.P) of aqueous extract daily for fourteen days and then sacrificed. Tissues were harvested and processed for photomicrographic examinations. Extracts of the plant gave an LD₅₀ value of 37 mg/kg (I.P) and histological alterations monitored. In the kidneys, there was acute tubular necrosis with diffused interstitial and glomerular haemorrhage characteristic of irreversible cellular injury of the epithelium and parenchyma. Similar changes were observed in the liver showing severe ballooning degeneration of the hepatocytes, necrosis and formation of mallory bodies. In the lungs diffused alveolar and capillary damage as well as early formation of hyaline membranes were evident. The histological changes are similar to those produced by chronic ethanol and *p-acetaminophene* ingestion, suggesting the presence of toxic constituents. From these observations, it can be inferred that the use of *S. longepedunculata* may be associated with tissue structural damage of some vital organs.

Key words: *Securidaca, longepedunculata*, histopathologic, heart, kidneys, liver, lungs, *Uwar-magunguna*.

INTRODUCTION

Securidaca longepedunculata is a shrub or small (2 – 10 m high) flowering savannah plant. The flowers are sweet scented, bright purple or violet in racemes, and the fruit is winged; the plant is widespread throughout tropical Africa. The common English names for the plant are: the violet tree, Rhodes's violet and wild vesteria. In northern Nigeria, It is called "*Uwar Magunguna*" in Hausa, literally translated "the mother of all drugs" a tribute to its very numerous medicinal uses. It is reputed to have over one hundred medicinal uses. In many parts of Africa, the plant is employed in traditional medicine principally for its psychotropic properties; aqueous extracts of this root are used as psychopharmacological agents (Winkelman and

Dobkin, 1989). The same authors confirmed the presence of ergot alkaloids in the extract.

The plant has been employed for various rheumatic and inflammatory diseases and as antihelminthic or purgative agents (Neuwinger, 1996). The use of the plant against snakebites, fish poisoning and in different diseases, have been documented (Olajide et al., 1998; Burkill, 1997; Neuwinger, 1996; Odebiyi, 1978). Its use in bacterial and malarial chemotherapy has also been investigated and documented (Msonthi, 1986; Akiniyi et al., 1996)

Despite the widespread use of *S. longepedunculata* in all parts of Africa, not much has been reported in the literature about its toxicity. The few reports available are in connection with its trypanocidal and insect toxicity where it is used as a stored grain preservative (Atawodi et al., 2003; Belmain et al., 2001).

When a herbal product is ingested, the body interacts

*Corresponding author. E-mail: xwelldapar@yahoo.com. Tel: +234 0803 703 6358.

with it in an attempt to get rid of any harmful toxins, especially if the body cannot convert the foreign substance into cellular components. These insults are commonly manifested by changes in enzyme levels and other cell components. The enzymes commonly involved include: aspartate aminotransferase (AST), alanine aminotransferase (ALT), creatine kinase (CK), amylase, and alkaline phosphatase. Also, components like urea and uric acid are vital diagnostic tools for toxicity. In a previous study, Wannang et al. (2005) found that aqueous extracts of the root bark of *S. longepedunculata* altered serum levels of these enzymes in rats; an indication of the potential toxicity of the plant. The toxicity could as well result in tissue or organ damage. The vital organs that are commonly affected are heart, liver, pancreas, and kidney among others. The aim of this study therefore, is to investigate the effect of the plant on tissue histology as a marker of toxicity.

MATERIALS AND METHODS

Rats

Adult white albino rats (Sprague Dawley strain) of both sexes (200 – 250 g) were purchased from the Animal House of the University of Jos, Nigeria. They were kept in clean cages under a 12/12 h normal light/dark cycle and allowed to adjust to the laboratory environment for a period of three (3) weeks before the commencement of the experiments. Food and water were provided *ad libitum* during the stabilization period.

Collection, identification and extraction of plant materials

The plant was collected from Federe in Jos East Local Government Area of Plateau State, Nigeria, in September 2005; it was identified as *S. longepedunculata* frens, family: Polygalaceae by Dr D. L. Wonnang of the Department of Botany, University of Jos, Nigeria. The roots were collected and carefully washed in clean water, and then oven dried for 72 h. They were subsequently reduced to coarse powder and 500 g of the powdered roots were extracted in 1000 ml of distilled water for 48 h at room temperature. The extract was filtered and a percentage yield of 38% (w/v) was obtained. This filtrate hereafter referred to as the extract used for this study.

Determination of LD₅₀

The method of Lorke (1983) was modified and used to determine the dose of the extract that would be lethal to 50% of the population of animals. Three dose points (10, 100 and 1000 mg/kg) were chosen for the pilot experiment, from which, doses of 30, 45 and 60 mg/kg respectively were administered to one animal per group in the second phase. The geometric mean of the highest non-lethal dose (with no deaths) and the lowest lethal dose (where death occurred) was calculated and taken as the LD₅₀ value.

Effect of extract on tissue morphology

Rats were treated by intra-peritoneal injection of 2 mg/kg extract daily for fourteen consecutive days then sacrificed by decapitation. The kidneys, liver, lungs, and heart were excised for light microscopic studies. Sections of each tissue were immersed immediately

in 250 ml of neutralized 10% (v/v) formalin. The tissues were kept in the fixative for 12 h, dehydrated with serial ethanol cycles (70% to absolute), and then embedded in paraffin. The paraffin-embedded tissue was cut into 5 µm sections. The tissue sections were deparaffinised and stained with Mayer hematoxylin and eosin stains for light microscopic analysis.

RESULTS

LD₅₀

In our study, administration of *S. longepeduncula* to rats, produced dose dependent multiple organ toxicities in the kidneys, the liver and the lungs. Estimation of LD₅₀ gave a value of 36.74 mg/kg in rats (Tables 1 and 2). Animals administered with the extract were calm. However, at the point of death they showed signs of respiratory distress (gasping) and muscle paralysis with a stretching of the hind limbs.

Table 1. Phase one of LD₅₀ investigation on the histopathologic effects of *Securidaca longepedunculata* on rats.

Group	Dose (mg/kg)	No. Used	No. Death
Control	-	3	-
1	10	3	0
2	100	3	3
3	1000	3	3

Table 2. Phase two of LD₅₀ investigation on the histopathologic effects of *Securidaca longepedunculata* on rats.

Group	Dose (mg/kg)	No. Used	No. Death
1	30	1	0
2	45	1	1
3	60	1	1

$$\begin{aligned} \text{LD}_{50} &= \sqrt{30 \times 45} \\ &= \sqrt{1350} \\ &= 36.74 \text{ mg/kg} \end{aligned}$$

Effect of extract on tissue morphology of rats

In the kidneys, the histopathologic changes were that of acute tubular necrosis with diffused interstitial and glomerular haemorrhage (Figures 1 and 2). This suggests that irreversible cellular injury affecting the epithelial parenchyma and endothelial cells occurred. Similar changes were observed in the liver in which, the hepatocytes exhibited severe ballooning degeneration with early steatohepatitis in some foci. In addition, massive hepatocyte necrosis with mallory body formation and extensive haemorrhage was also evident (Figures 3 and 4). In the lungs, diffused alveolar and alveolar capillary damage was observed with early formation of hyaline

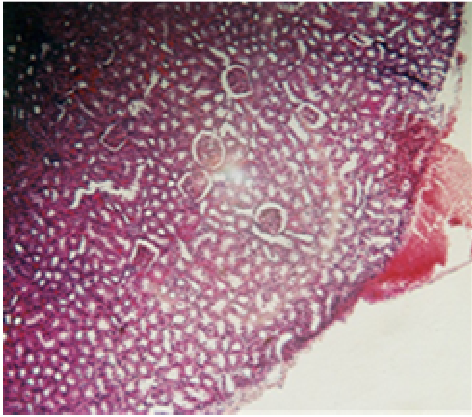


Figure 1. Normal kidney histology of rat.

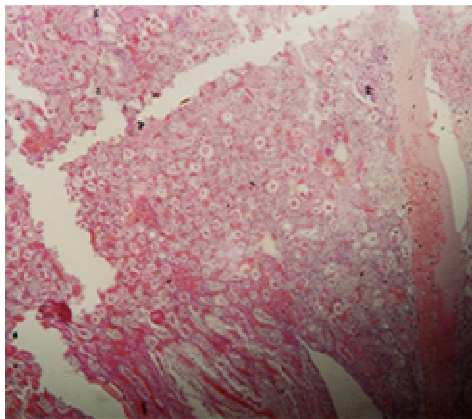


Figure 2. Kidney of *Securidaca longepedunculata*-treated rat showing areas of diffused interstitial and glomerular haemorrhage, tubular necrosis and hyaline casts.

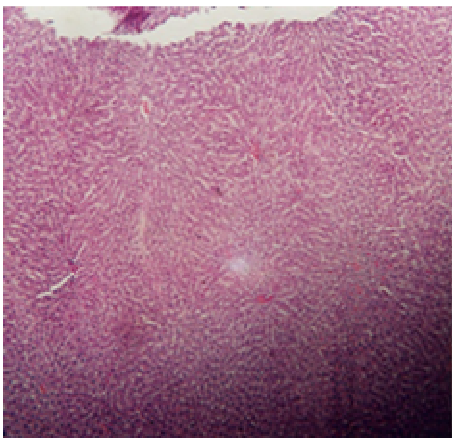


Figure 3. Liver histology of untreated rat.

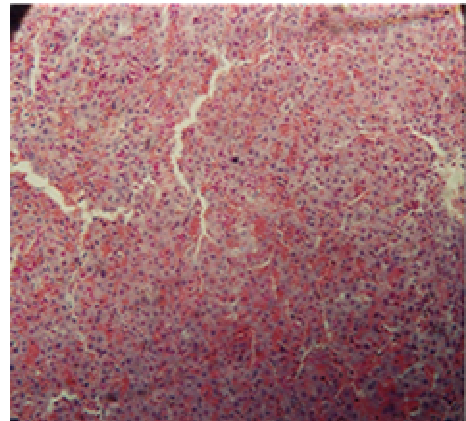


Figure 4. Liver of *Securidaca longepedunculata*-treated rat showing ballooning degeneration of hepatocytes and early fatty liver with the formation of Mallory bodies.

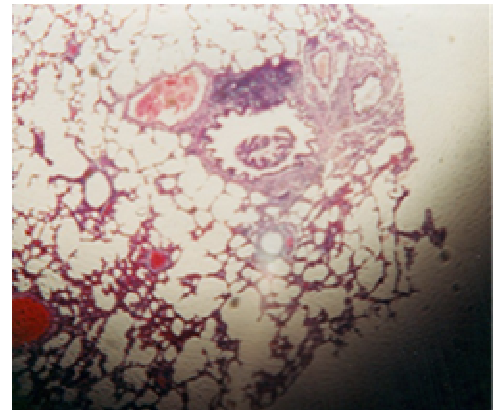


Figure 5. Lung of untreated rat showing normal histology.

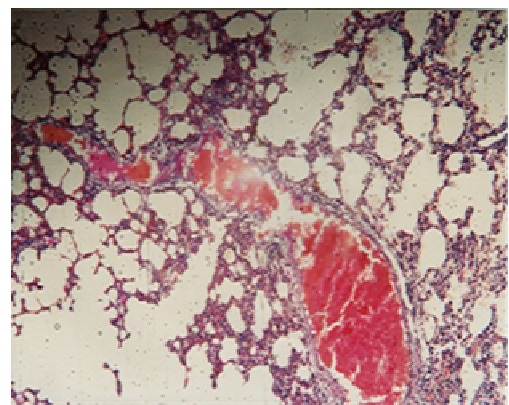


Figure 6. Lung of *Securidaca longepedunculata*-treated rat showing alveolar haemorrhage and vascular thrombosis.

membranes. The heart showed mild wavy contraction bands unremarkable of any significant change in the his-

tology of the myocardium (Figures 5 and 6).

DISCUSSION

Search of available literature revealed no published report on the toxicity of *S. longepedunculata* in humans despite the widespread use of the plant in various herbal remedies. In our study, intra-peritoneal administration of *S. longepedunculata* to rats, produced dose dependent multiple organ toxicities including the kidneys, the liver and the lungs. Estimation of LD₅₀ gave a value of 37 mg/kg in rats. This is of immense importance, in view of the large-scale human consumption of this plant and should be a matter of concern. However, LD₅₀ is not a very reliable procedure in the determination of toxicity as there is a wide variation in results between different species and even in the same specie under different experimental conditions. Moreover, LD₅₀ provides no information on what system failure led to the death of the animals. Some deaths may have been due to the quantity of the test substance causing gastric rupture or other morbidity unrelated to the toxicity of the extract. Notwithstanding, the LD₅₀ in conjunction with photomicrographs of stained tissues gave a good picture of the toxic characteristics of the plant.

Kidney histology of treated rats showed features consistent with renal epithelial injury from toxins. Many herbal preparations have been found to exhibit renal tubular necrosis showing extensive interstitial fibrosis and severe tubular loss most prominent in the outer cortex. Vanherweghem et al. (1993) and Mengs et al. (1982) showed that aristolochic acid was nephrotoxic in female Wistar rats which rapidly developed renal tubular necrosis and renal failure. The significance of this in traditional practice need to be evaluated especially because the plant has been found to exert hypoglycaemic properties (Kolawale et al., 2005), and some herbalists promote its use in diabetes mellitus a syndrome that is almost always associated with nephropathy.

Extract of *S. longepedunculata* significantly increased the levels of serum AST and ALT (Wannang et al., 2005). This is diagnostic of hepatocellular damage, as seen in disorders that cause the death of numerous liver cells (extensive hepatic necrosis) such as acute viral hepatitis A or B, pronounced liver damage inflicted by toxins as from an overdose of acetaminophen (paracetamol), and prolonged collapse of the circulatory system (shock) when the liver is deprived of fresh blood bringing oxygen and nutrients. Histological findings in this study are characterized by focal hepatocellular necrosis similar to the pattern of damage induced by paracetamol. In addition, fatty liver observed in the treated rats is similar to what is obtained in alcoholic cirrhosis.

Effect of the extract on pulmonary tissues does not indicate any specific pattern of toxicity; massive damage to alveoli and bronchiolar epithelium could have been a result of direct toxicity or could have resulted from transportation of toxic substances from other organs like the liver and kidneys to the lungs. This notwithstanding, res-

piratory toxicity of the plant is apparent even if the mechanism for this is not clear. Rats treated were observed to be in severe respiratory distress prior to death. These changes are similar to those found in acute or chronic ethanol-induced cell injury. The pathologic consequences of acute and chronic ethanol ingestion are multifactorial and multi-systemic. The mechanisms involved are complex and may include acetaldehyde production, generation of reactive oxygen species (free-radicals), lipid per-oxidation and cytokine expression (Mc Cain et al., 1989). The same workers also showed that peripheral blood monocytes from alcoholic hepatitis patients spontaneously produced TNF. TNF is believed to mediate most of tissue injury observed in alcohol consumption.

CONCLUSION

This study has demonstrated the tissue toxicity of *S. longepedunculata* in rats. Patients usually combine herbal remedies with orthodox medication or with alcohol; often without the knowledge of the pharmacist or the physician. Considering the potential toxicity of *S. longepedunculata* herbal practitioners should be educated on this especially when they recommend this plant as part of a complex regimen in the long term management of chronic illnesses like hypertension and diabetes. Further studies would be required to isolate the specific component(s) of the plant responsible for the toxicity in order to standardise the plant preparation for maximum therapeutic benefit.

ACKNOWLEDGEMENTS

The authors would like to acknowledge the assistance of Mr Thomas Yakubu of the Department of Pharmacognosy, University of Jos, for assisting in the extraction and phytochemical screening of the plant materials. We also appreciate the assistance of Mr. Gotom of the Department of Anatomy, University of Jos, for carrying out the histological procedures.

REFERENCES

- Akinniyi JA, Manawadu D, Sultanbawa M (1996). Ethnobotany and Ethnopharmacology of Nigerian medicinal Plants Research and Traditional Medicine in Malaria: In: State of Medicinal Plants Research in Nigeria: pp. 35-349.
- Atawodi SE, Bulus T, Ibrahim S, Ameh DA., Nok AJ, Mamman M, Galadima M (2003). *In Vitro* Trypanocidal Effect of Methanolic Extract of Some Nigerian Savannah Plants. Afr. J. Biotechnol. 2(9): 317-321,
- Belmain SR, Neal GE, Ray DE, Golob P (2001). Insecticidal and Vertebrate Toxicity Associated With Ethnobotanicals Used As Post Harvest Protectants In Ghana. Food Chem. Toxicol. 39: 287-291.
- Burkill HMP (1997). The Useful Plants of West Africa, Royal Botanic Gardens Kew 4: 447-458.
- Kolawole JA and Onyeché O.C (2005) Preliminary Screening of Aqueous Extract of the Leaves of *Securidacaca longepedunculata* for anti Hyperglycaemic Property; Nig. J. Pharm. Res. 4(2): 18-21.

- Lorke D (1983). A New Approach to Practical Acute Toxicity Testing, Arch. Toxicol. 54: 275-287.
- McCain CJ, Cohen DA. Increased tumour necrosis factor production by monocytes in alcoholic liver disease. Hepatology 1989; 9:349-351.
- Mengs U, Lang W, Poch JA (1982). The Carcinogenic Action Of Aristolochic Acid In Rats. Arch Toxicol. 51: 107-119.
- Msonthi JD (1986). The Status Of Medicinal Plant Research And Traditional Medicine In Malaria. In: The state of Medicinal plants Research in Nigeria. pp. 335-349
- Neuwinger HD (1996). African Ethnobotany, Poisons and Drugs Chemistry, Pharmacology, Toxicology Chapman and Hall, London, UK, pp. 743-753.
- Odebiyi OO (1978). Preliminary Phytochemical and Antimicrobial Examination of Leaves of *Securidaca Longepedunculata*. Nig. J. Pharmacol. 9: 29-30.
- Olajide OA, Awe SO, Makinde JM (1998). Pharmacological Screening of the Root Extract of *Securidaca Longepedunculata*. *Fitoterapia*, 69(3): 245-248
- Vanherweghem JL, Depierreux M, Tielemans C, Abramowicz D, Dratwa M, Jadoul M, Richard C, Vandervelde D, Verbeelen D Vanhaelen-Fastre R (1993). Rapidly Progressive Interstitial Renal Fibrosis In Young Women: Association With Slimming Regimen Including Chinese Herbs. Lancet. 341: 387-391
- Wannang NN, Wudil AM, Dapar LMP, Bichi LA (2005) Evaluation of anti-snake venom activity of the Aqueous root extract of *Securidaca longepedunculata* in rats. J. Pharm. Bio. Res. 2(2): 80-83.
- Winkleman M, Dobkin de Rios M (1989). Psychoactive Properties of Kung Bushmen Medicinal Plants. J. Psychoactive Drugs. 21: 51-59.