

Short Communication

Primary non Hodgkin's lymphoma of the orbit: A case report

Essadi¹ I, Tazi² EM, Allam² W, Sbitti¹ Y, Ichou¹ M and Errihani² H

¹Department of Medical Oncology, Military Hospital MOHAMMED V, Rabat, Morocco.

²Department of Medical Oncology, National Institute of Oncology, Rabat, Morocco.

Accepted 29 December, 2010

Lymphoma is the most common malignancy of the orbit and the eyelids, accounting for 10% of malignant orbital tumors in adults. Orbital lymphomas can arise primarily in the orbit or represent a manifestation of disseminated disease. In this paper we report a case of early stage orbital lymphoma, which was managed successfully with chemotherapy, and a review of the related literature. A Moroccan Muslim woman aged 76 years, who presented a left orbital swelling. Ophthalmological examination complemented by CT has objectified orbital mass, whose biopsy was in favour of a non Hodgkin's lymphoma (NHL) large cell B. The patient was classified as stage IE after a record expansion. She was managed successfully with 6 courses of Rituximab 375 mg/m², Cyclophosphamide 750 mg/m² d1, Doxorubicine 50 mg/m² d1, Vincristine 1.4 mg/m² d1, and prednisone 50 mg/m² d1-5 (R-CHOP) regimen, with complete response. This case highlights the important role of R-CHOP regimen for achieving successful treatment cure for patients having an early stage orbital lymphoma

Key words: Orbit, non hodgkin's lymphoma, large cell, chemotherapy.

INTRODUCTION

Lymphomas are malignant neoplasms of the lymphocyte cell lines. They mainly involve lymph nodes, spleen and other non-haemopoietic tissues. Orbital lymphomas represent 8 to 10% of all extranodal NHL, and only 1% of all lymphomas (Freeman et al., 1972).

Eighty percent of lymphomas are B-cell type, while 14% are T-cell type, with natural killer type (NK) forms only 6% (Fitzpatrick and Macko, 1984). Despite demonstrating an indolent course, with 60 to 80% of ocular adnexal B-cell lymphomas being localized at the time of diagnosis, they are renowned for recurrence in extranodal sites, including the lung, salivary glands, as well as other ocular adnexal sites (Fitzpatrick and Macko, 1984).

CASE REPORT

A Moroccan Muslim woman aged 76 years, who present a left eyelid swelling gradually increasing volume for three months. Ophthalmological examination disclosed

an orbital mass, developed outside the eyeballs with extension to the upper eyelid (Figure 1). Orbital CT was performed and disclosed a process measuring 4 cm with extension to the lacrimal glands and the upper eyelid (Figure 2). Biopsy with pathological examination and immunohistochemical study was for a large-NHL B cell CD20+ (Figure 3). Computed tomography of the chest, abdomen and pelvis was normal. A bone marrow biopsy showed no abnormalities. The patient was staged IE according to the Ann Arbor Staging system. She received 6 cycles of standard Rituximab 375 mg/m²d1, Cyclophosphamide 750 mg/m² d1, Doxorubicine 50 mg/m² d1, Vincristine 1.4 mg/m² d1, and prednisone 50 mg/m² d1-5 (R-CHOP) regimen. The response to the treatment was successful.

The status of her vision after chemotherapy was: 8 / 10 for the right eye and 9 / 10 for the left eye. At 6 months after chemotherapy she remains disease free. She is continuously followed by our group up to now (Figures 4 and 5).

DISCUSSION

Orbital lymphoma refers to a lymphoma occurring in the conjunctiva, lacrimal gland, eyelid and ocular

*Corresponding author. E-mail: ismail_onco@yahoo.fr.

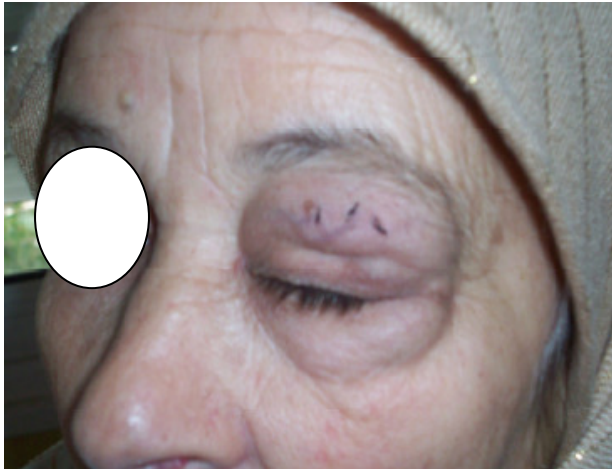

Figure 1. Left orbital mass.

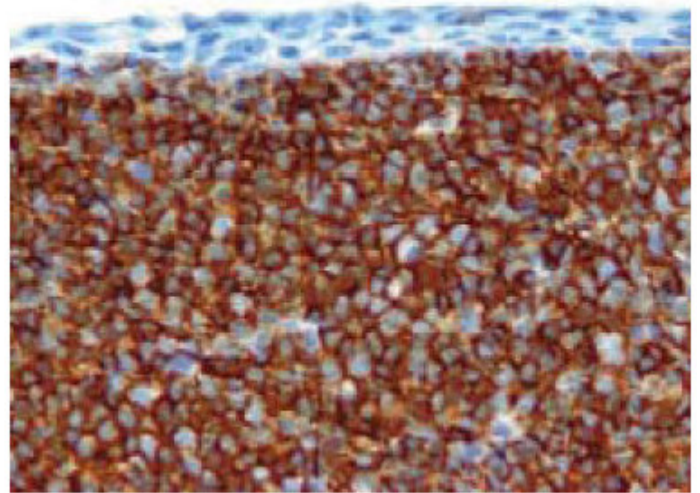


Figure 3. Large lymphoid cells marked by anti-CD20 (Marked anti-CD20 X 20).

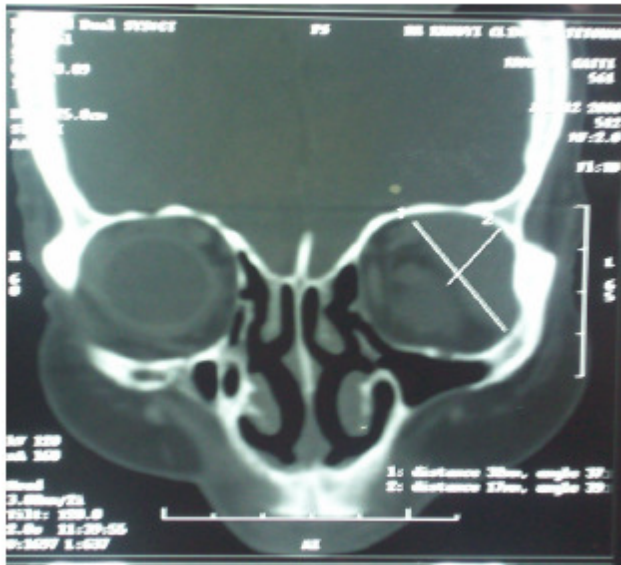

Figure 2. Orbital process with extension to the lacrimal glands and the upper eyelid.

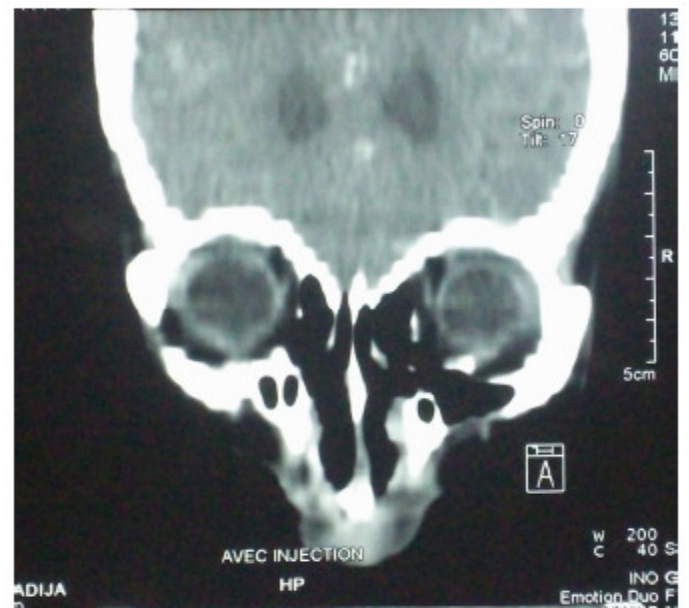

Figure 4. Complete response on CT scan.

musculature. Primary non-Hodgkin's lymphoma (NHL) of the orbit is a rare presentation, representing 8-10% of extranodal NHL (Freeman et al., 1972) and only 1% of all NHL (Fitzpatrick and Macko, 1984). Generally, it has an indolent course. Orbital lymphoma in contrast to ocular lymphoma is rarely associated with primary central nervous lymphoma. Majority of the orbital lymphomas are of low-grade variety (84%) and only 16% are of high-grade histology (Bessel et al., 1988). Orbital lymphomas are predominantly of mucosa associated lymphoid tissue (MALT) histology (57%), but they also include other histological subtypes, such as follicular lymphomas (19%), diffuse large B-cell lymphomas (DLCL) and mantle cell lymphomas (Coupland et al., 2002; Fung et

al., 2003). Orbital lymphoma may be unilateral or bilateral and up to 20% bilateral presentation is noted (Smitt and Donaldson, 1993). Most of the current literature consists of single institution retrospective reviews. The presenting age ranges from 15 to 70 years, but majority of orbital lymphomas occur around 60 years of age (Mittal et al., 1986). Most reports show a female predominance. Low-grade tumors are mainly localized to the orbit but high-grade tumors may extend to involve the bone, ethmoid sinuses and brain. Bilateral orbital involvement is seen in about 10 to 25% of patients (Smitt and Donaldson, 1993). For local evaluation, a thorough ophthalmological




Figure 5. Clinical complete response.

examination is carried out in the beginning. Restricted ocular motility and visual impairment are the features elicited by the ophthalmologist. Systemic lymphomatous involvement may be associated in 20% of cases and thorough clinical examination of opposite orbit, oral cavity and oropharynx is mandatory along with systemic examination. In addition, symptoms of peptic ulcer disease in this patient population should be evaluated endoscopically. Surgery alone is seldom used except for conjunctival lesions. There is a high relapse rate after surgery as reported by many authors (Esik et al., 1996).

This high recurrence rate may reflect difficulty in performing a radical procedure and preserving function. Esik et al. (1996) reported 0% local relapse free survival at 10 years in patients treated with surgery alone. Local relapses after surgery alone can be effectively treated with radiotherapy leading to complete response; however, the cosmetic outcome may be worsened by two therapies. Except for biopsy, surgery has no role in this disease. High-grade tumors should be treated with standard combination chemotherapy, cyclophosphamide, adriamycin, vincristine and prednisone (CHOP). The current treatment of choice for elderly patients with DLCL is that of CHOP chemotherapy with rituximab (an anti CD-20 monoclonal antibody) or the rituximab cyclophosphamide adriamycin (vincristine) oncovin prednisolone (RCHOP) regimen. This is based on a recent European study (Coiffier et al., 2002) which studied CHOP vs. R-CHOP in elderly patients with DLCL and showed significant prolongation of event-free survival CHOP without additional toxicity. The role of and overall survival in the group that was treated with R-chemotherapy has not yet been clearly defined for low

grade tumors. Major prognostic criteria for orbital adnexal lymphomas include anatomic location of the tumor; stage of disease at first presentation; lymphoma subtype as determined using the revised European American Lymphoma (REAL) classification; (Martinet et al., 2003) Immunohistochemical markers determining factors such as tumor growth rate; and the serum lactate dehydrogenase level (LDH) (Coupland et al., 2002). In a rare cancer network study of 90 patients by Martinet et al. (2003) the statistically significant factors on univariate analysis were younger age, low grade, normal erythrocyte sedimentation rate, absence of muscular infiltration, complete response to treatment, conjunctival localization, and normal LDH for overall survival, disease-free survival and freedom from treatment failure. In multivariate analysis, the favorable factors were younger age and low grade for overall survival and disease-free survival; a favorable response, conjunctival localization, and complete staging were highly significant for disease-free survival and freedom from treatment failure.

CONCLUSION

This case highlights the important role of R-CHOP regimen for achieving successful treatment cure for patients having an early stage orbital lymphoma

REFERENCES

- Freeman C, Berg JW, Cutler SJ (1972). Occurrence and prognosis of extranodal lymphomas. *Cancer*. 29: 252-260.
- Fitzpatrick PJ, Macko S (1984). Lymphoreticular tumors of the orbit. *Int. J. Radiat. Oncol. Biol. Phys.*, 10: 333-340.
- Bessel EM, Henk JM, Wright JE, Whitelocke RA (1988). Orbital and conjunctival lymphoma: Treatment and prognosis. *Radiat. Oncol.*, 13: 237-244.
- Coupland SE, Hummel M, Stein H (2002). Ocular adnexal lymphomas: Five case presentations and a review of literature. *Surv Ophthalmol*; 47: 470-490.
- Fung CY, Tarbell NJ, Lucarelli MJ, Goldberg SI, Linggood RM, Harris NL, Ferry A (2003). Ocular adnexal Lymphoma: Clinical behaviour of distinct World Health Organization classification of subtypes. *Int. J. Radiat. Oncol. Biol. Phys.*, 57: 1382-1391.
- Smitt MC, Donaldson SS (1993). Radiotherapy is successful treatment for orbital lymphoma. *Int. J. Radiat. Oncol. Biol. Phys.*, 26: 59-66.
- Mittal BB, Deutsch M, Kennerdell J, Johnson B (1986). Paraocular lymphoid tumors. *Radiology*. 159: 793-796.
- Esik O, Ikeda H, Mukai K, Kaneko A (1996). A retrospective analysis of different modalities for treatment of primary orbital non-Hodgkins lymphoma. *Radiother Oncol.*, 38: 13-18.
- Coiffier B, Lepage E, Briere J, Herbrecht R, Tilly H, Bouabdallah R (2002). CHOP chemotherapy plus rituximab compared with CHOP alone in elderly patients with diffuse large B-cell lymphoma. *N. Engl. J. Med.*, 346: 235-242.
- Martinet S, Ozsahin M, Belkacemi Y, Landmann C, Poortmans P, Oehlere C, Scandolaro I, Krenkli M, Maingon PH, Miralbell R, Studer G, Chauvet B, Marnitz S, Zouhair A, Mirimanoff R (2003). Outcome and prognostic factors in orbital lymphoma: A Rare Cancer Network study on 90 consecutive patients treated with radiotherapy. *Int. J. Radiat. Oncol. Biol. Phys.*, 55: 892-898.