

## Case Report

# Diagnostic challenges in a case of recurrent hemoptysis

R. K. Gupta\* and Huda Bukharie

King Fahd Hospital of University, University of Dammam, Kingdom of Saudi Arabia.

Accepted 25 January, 2011

**Actinomycosis is an uncommon disease in children and most cases are of cervicofacial infections. To date there have been only few case reports on children with thoracic actinomycosis which may mimic malignancy, lymphoma or tuberculosis. Here, we report a 14-year old boy, presented with recurrent hemoptysis and diagnosed as thoracic actinomycosis on the basis of CT and typical histopathological findings. The patient was treated successfully with specific antibiotics.**

**Key words:** Actinomycosis, hemoptysis, rigid bronchoscopy.

## INTRODUCTION

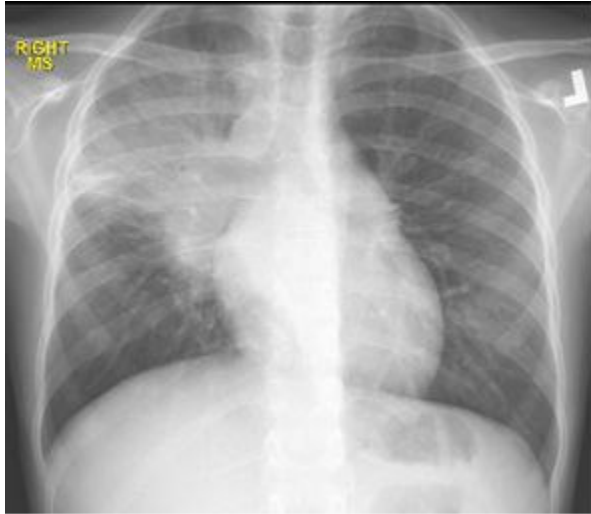
Actinomycosis is a chronic granulomatous disease of cervicofacial (55%), abdominal (20%) or thoracic (15%) locations that is caused by *Actinomyces israelii* (Russo, 1995). Pulmonary actinomycosis is rare in children and because of its non-specific clinical presentation, it is commonly confused with either suppurative lung disease or malignancy (Whitworth and Jacobes, 2003; Mabeza and Macfarlane, 2003). The diagnosis depends on the characteristic histological findings of sulfur granules or the isolation of actinomyces on culture. A long course of penicillin is the treatment of choice. In this report, we present a 14 year-old boy with long standing recurrent hemoptysis. He was diagnosed as actinomycosis on the basis of histological findings and treated successfully with penicillin.

## CASE REPORT

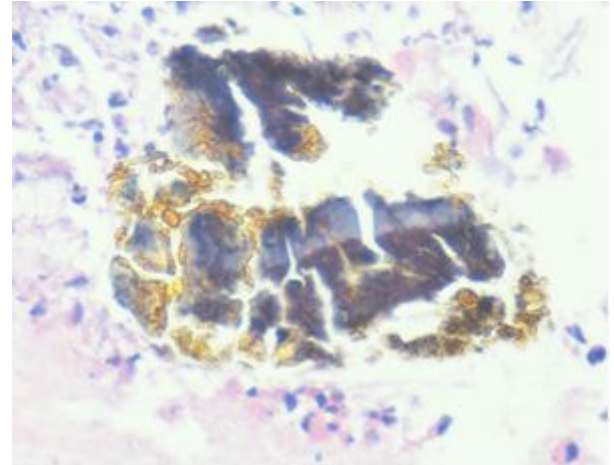
A 14 year-old previously healthy boy admitted to our tertiary hospital, King Fahd University Hospital, Kingdom of Saudi Arabia with a six months history of off and on hemoptysis. There was no history of fever, weight loss, cough, expectoration or chest pain. His past and family histories were unremarkable. On physical examination, he was afebrile and his vitals were within normal range. There was no palpable lymphnode, icterus, clubbing,

cyanosis or edema. He had poor oral hygiene with dental caries. His respiratory system examination revealed decreased chest movements of the right side, percussion notes were found to be dull over the right middle lung field and auscultation over this area revealed coarse crepitations. Chest radiograph showed a homogenous consolidation of the right middle lung zone (Figure 1). Laboratory investigations showed that his hemoglobin was 8.9 gm%, leukocyte count was 8,100/mm<sup>3</sup> with 61% neutrophils, 29% lymphocytes, 0.7% monocytes and 0% eosinophils. The patient's Erythrocyte Sedimentation Rate (ESR) was 100 mm/h. His C reactive protein was negative. His renal function test, electrolytes and liver function tests were within normal limits. His repeated sputum examination for Acid Fast Bacilli (AFB) stain and other organisms was found to be negative. His Purified Protein Derivative (PPD) skin test was non-reactive. His Contrast Enhanced Computed Tomogram (CECT) of the thorax showed a soft tissue lesion involving the whole superior segment of the right lower lobe with the central area of low attenuation associated with pleural thickening (Figure 2). The patient further underwent a Fiber Optic Bronchoscopy (FOB), which revealed an irregular granular thickening of the bronchial mucosa near the opening of the superior segment of the right lower lobe associated with narrowing of the lumen. Bronchial biopsy using FOB from the visible lesion and bronchial lavage was performed from the same segment for histopathological, cytological and microbiological analyses. The biopsy as well as the lavage was found to be inconclusive for any definitive diagnosis. Before considering open surgical intervention, rigid bronchoscopy

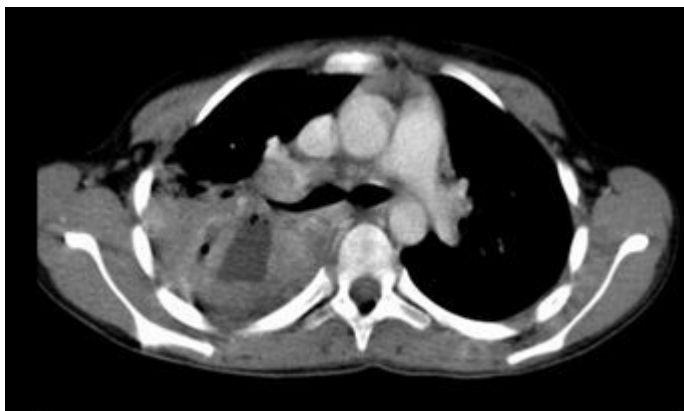
\*Corresponding author. E-mail: [drkkgupta70@yahoo.com](mailto:drkkgupta70@yahoo.com). Tel: 00966560636040.



**Figure 1.** PA chest x-ray: right middle and upper zone homogenous lesions.

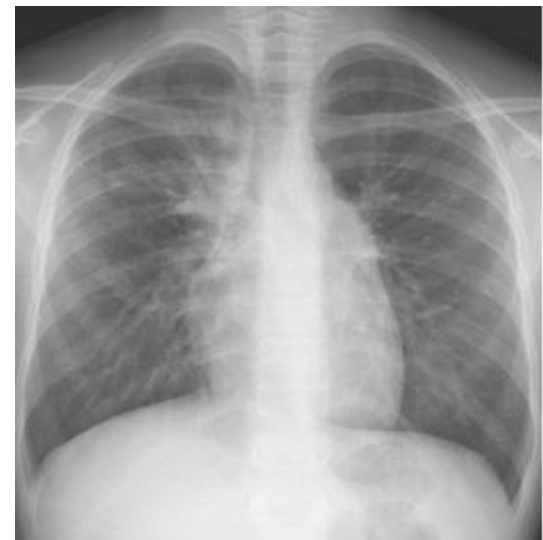

**Figure 3.** Pathology of bronchial biopsy section showing micro abscesses with filamentous gram-positive bacteria surrounded by neutrophils cells typical of Actinomycosis colony.



**Figure 2.** Contrast –enhanced CT scan of thorax showing tissue lesion involving the whole superior segment of the right lower lobe with central low attenuation with pleural thickening.

was done under general anesthesia and biopsy with lavage from the same lesion was repeated. At this time, the histopathological examination revealed colonies consistent with actinomycosis bacteria focally surrounded by neutrophils (Figure 3). However, no organism was isolated from the bronchial lavage. Histopathology and bronchial lavage was found to be negative for malignant cells. A diagnosis of pulmonary actinomycosis with endobronchial extension was made and the patient was put on intravenous Ceftriaxone 2000 mg every 24 h. Ceftriaxone was continued for one month followed by oral Amoxicillin (875 mg) and Clavulanate (125 mg) combination every 12 h for the next 9 months. During this period, the patient's hemoptysis was completely resolved, ESR dropped to 18 mm/h and follow-up radiology after 6 and 9 months indicated clear improvement (Figure 4).



**Figure 4.** PA Chest X Ray after six months of treatment.

## DISCUSSION

The genus *Actinomyces* are Gram-positive, non-spore-forming, predominantly anaerobic prokaryotic bacteria belonging to the family Actinomyceataceae. *Actinomyces* are commensals of the human oropharynx, gastrointestinal tract and female genitalia. Out of fourteen species which have been clearly characterized to date, *A. israeli* is the organism most commonly incriminated in human disease (Smego, 1998). Actinomycosis infection has been reported around the world with decreasing incidence (Russo, 1995). Invasive actinomycosis affects the cervicofacial region in 55% of cases, the

abdomen in 20% of cases and the thorax in only 15% of cases (Russo, 1995). Males are affected three times more than females and most series describe a clear peak incidence in the 4th and 5th decades (Lee and Rudoy, 2003). Thoracic actinomycosis usually results from the aspiration of oropharyngeal or gastrointestinal secretions into the respiratory tract (Lu et al., 2003). Predisposing factors usually include poor dental hygiene or dental caries, underlying respiratory disorders, periodontal disease, paranasal sinusitis, immunocompromised status and mentally subnormal status in children (Lee and Rudoy, 2003). In our case, the presence of dental caries and poor dental hygiene are probably the predisposing factors. Chien-Heng et al. (2010) recently reported a case of pulmonary actinomycosis with lower chest wall involvement in a previously healthy 10-year old girl and the route of infection was thought to be from the aspiration of oropharyngeal secretions.

Pulmonary actinomycosis usually present as a mass in the mediastinum or lung. It can also manifest as diffuse or local pneumonia, or an endobronchial mass. The disease sometimes invades adjacent tissues such as the pleura, chest wall, bony structure inducing bone resorption, pericardium and diaphragm. The formation of fistulas and sinus tract can make the bacteria cross the diaphragm into the abdomen or can make discharging skin sinuses from the chest wall that are seen in approximately 11% of cases (Chien-Heng et al., 2010). Complications such as empyema or hematogenous dissemination can occur if diagnosis is delayed (Mabeza and Macfarlane, 2003). In our patient, the disease presented as a lung mass with endobronchial lesion.

Most individual present with cough, chest wall pain, weight loss and fever. Less common, patients may have hemoptysis (Lu et al., 2003). In the present case, hemoptysis was the only complaint because of endobronchial extension of the disease which was later confirmed during bronchoscopy. Chest X-ray is very non-specific to suspect the diagnosis of actinomycosis as compared to the chest CECT which may provide more information. It is characterized by segmental, patchy air-space consolidation containing low attenuation areas with peripheral enhancement and adjacent pleural thickening (Cheon et al., 1998). The chest CT scan in our patient showed the characteristic soft tissue lesion involving the whole superior segment of the right lower lobe with the central area of low attenuation and adjacent pleural thickening. Sometimes, thoracic actinomycosis lacking classic signs may mimic tuberculosis (Gaussard et al., 1999) or neoplasia such as leukemia, lymphoma, langerhans cell histiocytosis or solid tumors and patients are evaluated for suspicion of malignancy (Mabeza and Macfarlane, 2003)

The diagnosis of pulmonary actinomycosis is confirmed by positive culture and pathological findings of sulfur granules or branching filaments with a radial pattern in the microabscess foci surrounded by purulent exudates in the tissue specimens. Shin'ichi et al. (1998) reported that

granulation tissue obtained by Transbronchial Lung Biopsy (TBLB) was considered an important finding suggestive of pulmonary actinomycosis. In our case, bronchial biopsy taken from the granulation tissue using rigid bronchoscope confirmed the diagnosis and excluded malignancy. The specimen obtained during FOB may not be adequate to reveal the characteristic histopathological finding. However, surgical intervention is usually necessary to confirm the diagnosis (Lee and Rudoy, 2003).

Our case was suspected as pulmonary actinomycosis on the basis of radiological presentation and confirmed by histopathology. Before the final diagnosis could be made, it was a big diagnostic dilemma for us as the fiber optic bronchoscopy that was performed in the beginning remained inconclusive for any diagnosis. The next step in such a situation according to previously reported literature should be surgical intervention but in our case, we took a chance and repeated the biopsy using rigid bronchoscopy for better tissue yield. Therefore, definite diagnosis was established in this patient and avoided surgical intervention.

We therefore recommend rigid bronchoscopy in such cases before considering surgical options. It is also highlighted through this case that rigid bronchoscopy is superior to FOB for better diagnostic yield and should be considered as a first choice of intervention. The disease should be treated with high doses of antimicrobials for a prolonged period (Choi et al., 2005). The antibiotic of choice is penicillin (Bennhoff, 1984) and alternatives include erythromycin, tetracycline, clindamycin, cephalosporins, meropenam and chloramphenicol (Choi et al., 2005). Our case was treated successfully with intravenous Ceftriaxone for one month and later received oral antibiotics (amoxicillin and clavulanic acid) for the next nine months. Surgical interventions are sometimes required to treat complications like massive hemoptysis, empyema or chronic bronchial suppuration.

In conclusion, thoracic actinomycosis should be considered in the differential diagnosis of mass lesions even in the absence of typical features such as discharging sinuses. Rigid bronchoscopy should be considered first for tissue biopsy and histopathological diagnosis. Once early diagnosis is made, prognosis is excellent with specific antibiotic and surgical intervention can be completely avoided.

## REFERENCES

- Russo TA (1995) Agents of actinomycosis. In: Mandell GL, ed. Principles and Practice of Infectious Disease. 5th edn. New York, Churchill Livingstone, pp. 2645–2654.
- Whitworth S, Jacobes RF (2003) Actinomycosis. In: Feigin RD, Cherry JD, Demmler GJ, Kaplan SL (eds). Textbook of Pediatric Infectious Diseases, 5th edn. WB Saunders, Philadelphia,; 1776–80.
- Mabeza GF, Macfarlane J (2003). Pulmonary actinomycosis. Eur. Respir. J., 21: 545–51.
- Lee JP, Rudoy R (2003). Pediatric thoracic actinomycosis. Hawaii Med. J., 62: 30–32.

- Lu MS, Liu HP, Yeh CH, Wu YC, Liu YH, Hsieh MJ et al (2003). The role of surgery in hemoptysis caused by thoracic actinomycosis; a forgotten disease. *Eur J Cardiothorac Surg.*, 24: 694-698.
- Bennhoff DF (1984). Actinomycosis: diagnostic and therapeutic considerations and a review of 32 cases. *Laryngoscope*, 94: 1198-1217.
- Smego RA, Foglia G (1998). Actinomycosis. *Clin. Infect. Dis.*, 26: 1255-1263.
- Chien-Heng L, Wei-Ching L, Yung-JenH, Chia-LinC, Fang-ChingL, Chieh-MoL (2010) Pulmonary actinomycosis with remote lower chest wall involvement in an immunocompetent child. *Pediatr. International*, 52: 129-131.
- Shin'ichi H, I Yoshiki, K Satoshi (1998). Clinical and Radiological Study of Pulmonary Actinomycosis. *J. Japanese Respiratory Soc.*, 36: 999-1005
- Cheon JE, Kim MY, Lee JS, Choi GM, Yeon KM (1998). Thoracic actinomycosis: CT findings. *Radiology*, 209: 229-33.
- Gaussard P, Gie R, Beyers N (1999). Thoracic actinomycosis mimicking primary tuberculosis. *Pseiatr. Infect. Dis. J.*, 18: 473-475
- Choi J, Koh WJ, Kim TS (2005) Optimal duration of IV and oral antibiotics in the treatment of thoracic actinomycosis. *Chest*, 128: 2211-7.