

Full length Research Paper

# Investigation of *Demodex* spp. in perinea areas and faces of young men visiting the urology polyclinic

Haluk Soylemez<sup>1</sup>, Ali Beytur<sup>2</sup>, İlhan Gecit<sup>2</sup>, Ulku Karaman<sup>3\*</sup>, Ali Ozer<sup>4</sup> and Sinan Calik<sup>5</sup>

<sup>1</sup>Private Müjde Hospital, Urology Clinic, Malatya, Turkey.

<sup>2</sup>Beydağı State Hospital, Urology Clinic, Malatya, Turkey.

<sup>3</sup>Ordu University, School of Health, Ordu, Turkey.

<sup>4</sup>Department of Public Health, Sutcu İmam University, Kahramanmaraş, Turkey.

<sup>5</sup>Department of Statistics, Elazığ Fırat University, Turkey.

Accepted 23 July, 2010

It has been reported that types of *Demodex* can be transmitted to other people through close contact and they can play a pathogenic role in rosacea, acne vulgaris, perioral dermatitis, seborrheic dermatitis, micropapillary-pruritic dermatitis, and blepharitis. Types of *Demodex* are reported to be located in various places of human body. The purpose of the present study was to detect the presence of *Demodex* spp. in the samples taken from the faces and perinea areas of the young men using standardized surface skin biopsy (SSSB). Accordingly, samples were obtained using SSSB method from the faces and perinea areas of 200 men aged 19 - 34, which were then covered with entellan and sent to the parasitological laboratory. *Demodex* spp. was found in 42.0% of the samples taken from perinea area and in 83.0% of the samples taken from subjects' faces, while *Enterobius vermicularis* was detected in two cases. One of the samples taken from was *Demodex brevis*, while the others were *Demodex folliculorum*. It was concluded that, given that species of *Demodex* can be found in perinea area under conditions of collective accommodation, specimens should be taken from patients consulting with pruritus or allergic reactions in order to diagnose the parasite, and treatment protocol should be planned according to the results of the analysis.

**Key words:** *Demodex* spp., facies, perinea and cheek.

## INTRODUCTION

It has been reported that among the *Demodex* spp. species *Demodex folliculorum* and *Demodex brevis* usually settle in the pilosebaceous units in the hair follicles on human face. It is also stated that *D. folliculorum* survive alone or in groups in follicular spaces, whereas *D. brevis* live alone in the depths of sebaceous glands and the thin and long structures of the mites are suitable for these places (Erbagci and Ozgoztasi, 1998; Wesolowska et al., 2005).

It has been reported that the immunologic reactions developed against the parasite as a result of the proliferation of *D. folliculorum* due to immunological defects play a role in emergence of skin lesions (Dong and Duncan, 2006). It has also been reported that

species of *Demodex* are found in various places of human body including nasolabial region, base of eyelashes, chin, forehead, outer ear canal, nipple, back, penis and hips (Baima and Sticterling, 2002; Nutting, 1976). The first case of *Demodex* was detected by (Saygi et al., 1984) in perinea area using cellophane tape method.

Methods used for diagnostic purposes include cellophane tape, skin scraping, punch biopsy and standardized surface skin biopsy (SSSB). Among these diagnostic methods SSSB is an effective one in terms of detecting the mite intensity of the parasite per cm<sup>2</sup>, since it is able to collect completely the follicular content together with the surface part of the stratum corneum where the species of *Demodex* inhabit (Erbagci and Ozgoztasi, 1998; Forton et al., 2005). It was aimed in this study to detect the presence of *Demodex* spp. In the samples taken from the faces and perinea areas of the young men with SSSB.

\*Corresponding author. E-mail: [ulkukaraman@yahoo.com](mailto:ulkukaraman@yahoo.com).

## MATERIALS AND METHODS

Prior to the study, health staff working in urology polyclinic were given an applied in-service training by a parasitologist about *Demodex* species and their parasitism, the purpose of the study and planned procedures, how to obtain specimens from women's perineal area using SSSB method. The specialized doctors who would obtain the specimens practiced on volunteering subjects. After the surface part of the stratum corneum together with the hair follicles on the specimens was observed, the evaluation began.

The research group included 200 male patients aged 19 - 34 who visited the urology polyclinics. Among the patients, those who were detected to have pruritus and blishes in the perineal area based on their histories were informed comprehensively about the present research by the specialized doctor, and specimens taken from the perineal area of the volunteering subjects using SSSB method were sent to the parasitological laboratory after being covered with entellan. Specimens were examined in parasitological laboratories through light microscope at X100 and X400 magnification. Even if one *Demodex* spp. was observed, it was considered as positive. Parasite intensity of 5 and more per cm<sup>2</sup> of samples taken from face was considered as positive. Patients with *Demodex* spp. positive were first informed about the results and forwarded to the relevant polyclinic.

Statistical analyses were done using Student *t* test for independent samples, Yates' corrected chi-square test, and Fisher's exact test. The data were presented in terms of mean values, standard deviation, number, and percentage. The statistical significance was considered as  $p < 0.05$  and analyses were done using SPSS 13.0 software.

## RESULTS

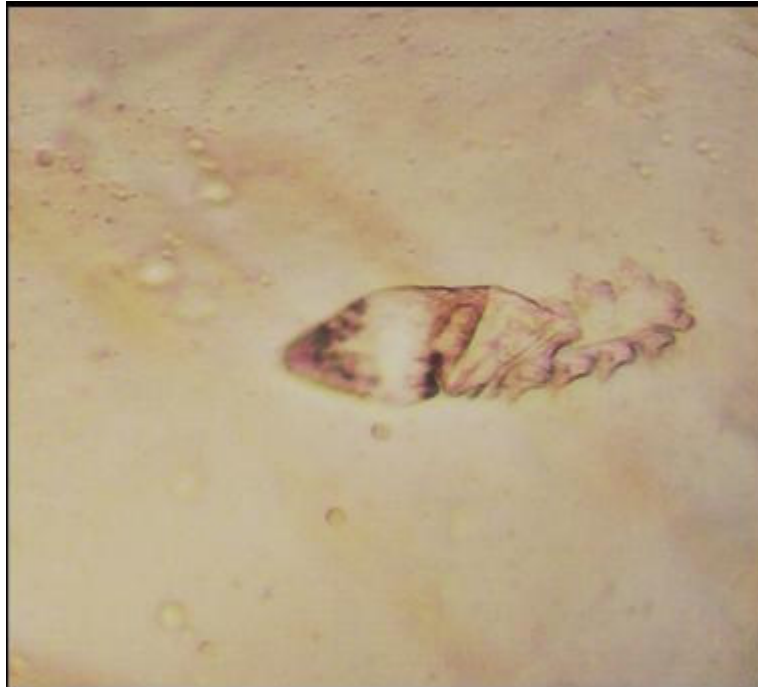Specimens were taken from faces and perineal areas of 200 men aged 19 - 34 using SSSB method, covered with entellan, and sent to the parasitological laboratory. The examination revealed the presence of *Demodex* spp. among 42.0% of the specimen from perineal (Figure 1) and among 83.0 % of the specimens from face (Figure 3 - 4), and *Enterobius vermicularis* in 2 of the specimens from perineal (Figure 2). One of the specimens from face was *D. brevis*, while the others were *D. folliculorum*. The relationship between the presence of *Demodex* on face and pruritus complaints is shown in Table 1.

Fisher's Exact Test was used in Table 1,  $p = 0.54$ . No significant relationship was found between the presence of *Demodex* on face and pruritus complaint ( $p = 0.54$ ). The relationship between pruritus in perineal area and the presence of *Demodex* is given in Table 2. Yates' corrected chi-square was used in Table 2, which revealed no significant relationship ( $p = 0.69$ ). The percentages on the co-existence of *Demodex* on face and perineal area are shown in Table 3. Yates' corrected chi-square was used in Table 3, which revealed no significant relationship ( $p = 0.54$ ). The statistics about age, barrack size (number of men in a barrack) and presence of *Demodex* are shown in Table 4. Independent samples test was applied, and no significant differences in age and barrack size were found between presence and absence of *Demodex*.

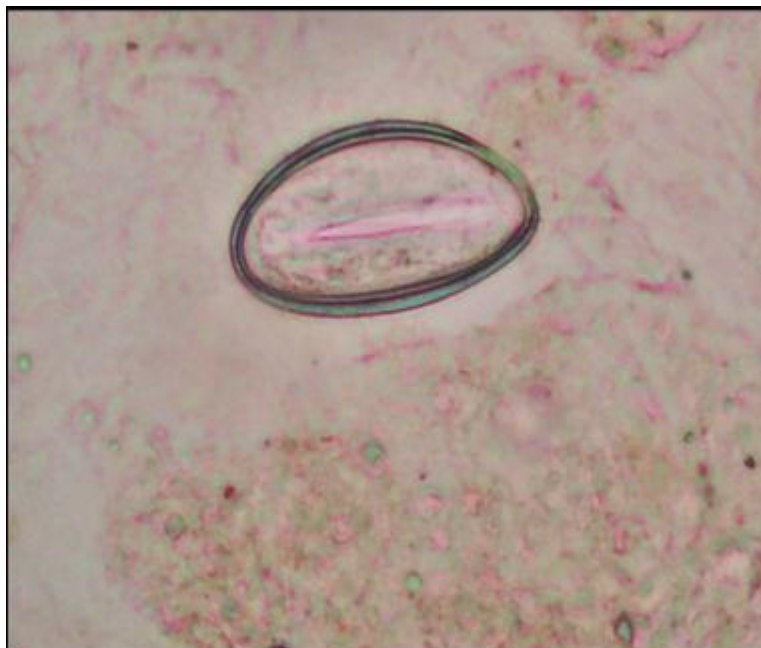
## DISCUSSION

With regard to the pathological and clinical symptoms caused by different types of *Demodex*, some researchers consider the inhabitation of *Demodex* spp in pilosebaceous follicles as harmless, while others have reported that *D. folliculorum* can play an etiopathogenic role in rosacea, acne vulgaris, blepharitis, perioral dermatitis, pustular folliculitis, papular-pustular lesions on hairy skin, and pustular lesions in acquired immune deficiency syndrome (Dong and Duncan, 2006; Mathieu and Wilson, 2000; Wesolowska et al., 2005). In various researches about the epidemiology of types of *Demodex*, (Akdeniz et al., 2002) found that the density of *D. folliculorum* among diabetic patients was significantly higher than control group. Similarly, in a research on patients with chronic kidney failure, Ozçelik et al. (2007) found the parasite in 12.76% of the 47 patients. In a different study Ding and Huang (2005) examined the outer ear canal secretion of 613 healthy high school students and found *Demodex* in 11.58% of them. Also Karaman et al. (2008) reported the presence of *Demodex* spp. in 15.3% of the hairy skin biopsies diagnosed keratinized cyst, trikelemlal cyst, nevus, dermatitis, carcinoma and inflammation. Forton et al. (1993) reported that in specimens obtained from 49 patients with rosacea using SSSB they found the density of *D. folliculorum* about 10.8/cm<sup>2</sup>, which was significantly higher than the control group. Moreover, the researchers stated that SSSB is an effective method measure *D. folliculorum* density easily. Again in a research to evaluate the *D. folliculorum* pathogenesis in rosacea Abd-El et al. (1997) found the mite density as 28.6/cm<sup>2</sup> in randomly chosen 16 patients with papulopustular rosacea problem and 6.9/cm<sup>2</sup> in control group. Similarly, Roihu et al. (1998) reported the presence of *Demodex* in 51% of 80 patients with rosacea, 28% of the 40 patients with egsema and 31% of the 40 patients with lupus erythematosus.

Sener et al. (2009) aimed to detect the positivity of *Demodex* spp. in biopsy specimens of skin diagnosed as nevus. In the study the specimens obtained from 110 patients diagnosed with nevus 43 (39.1%) out of 110 specimens were detected to have *Demodex* spp. *Demodex* colonization augmented in nevi can be explained by the possible affinity of the parasite to the melanin pigment. It was reported that the prevalence of *Demodex* species increases as the patients grow older. Aycan et al. (2007) reported *Demodex* prevalence in 20% of the  $\leq 20$  age group and in 53.5% of the  $21 \leq$  age group. In their study to evaluate the relation between presence of *Demodex* spp. and age (Baysal et al. 1997) found 8.3% positivity among 11 - 15 age group and 12.7% positivity among 16 - 20 age group. It has been reported that *Demodex* types do not appear among children and increase as of adolescence and peak in older ages. This finding can be interpreted as a result of lack of considerable differences between the ages of the participating



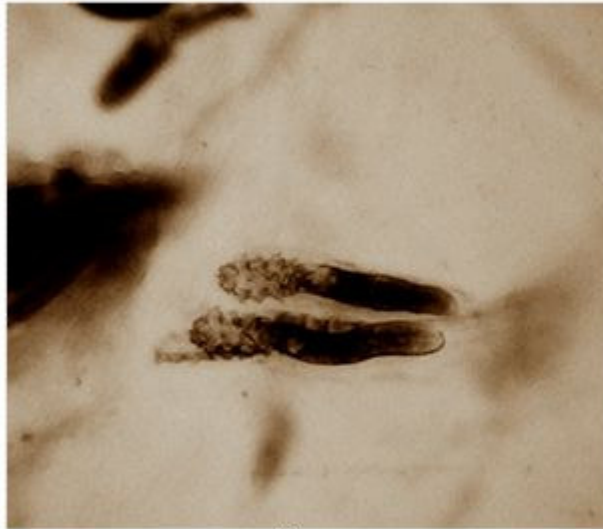
**Figure 1.** Adult *Demodex* spp. 100X.



**Figure 2.** *E. vermicularis* egg 100X.

men. As far as the relevant literature was scanned, no researches about the epidemiology of *Demodex* have been reported on the face and perinea area of the young men. Yet, Ugraş et al. (2009) examined the specimens obtained from the perianal area of 100 men and found no *Demodex* presence. As a result of the present study, we

found *Demodex* spp. in 42.0% of the specimens from perinea and in 83.0% of the specimens from face, and *E. vermicularis* in two of the specimens taken from 0.2% *Taenia* spp. eggs, and 0.2% *Phthirus pubis*. Saygi et al. (1984) reported *Demodex* spp. in perineal area material using cellophane tape method. These findings are similar



**3**



**4**

**Figures 3 and 4.** Adult *Demodex* spp. in specimens from face 100X.

**Table 1.** The relationship between the presence of *Demodex* on face and pruritus complaint.

	<i>Demodex</i> on face					
	Yes		No		Total	
	Number	(%)	Number	(%)	Number	(%)
<b>Pruritus on face</b>						
Yes	29	16.3	149	83.7	178	100.0
No	5	22.7	17	77.3	22	100.0
Total	34	17.0	166	83.0	200	100.0

**Table 2.** The relationship between the presence of *Demodex* and pruritus in perinea.

	<i>Demodex</i> in perinea					
	Yes		No		Total	
	Number	(%)	Number	(%)	Number	(%)
<b>Pruritus in perinea</b>						
Yes	101	59.2	70	40.9	171	100.0
No	16	55.2	13	44.8	29	100.0
Total	117	58.5	83	41.5	200	100.0

**Table 3.** Presence of *Demodex* on face and perinea.

	Pruritus in perinea					
	No		Yes		Total	
	Number	(%)	Number	(%)	Number	(%)
<b><i>Demodex</i> on face</b>						
No	22	64.7	12	35.3	34	100.0
Yes	95	57.2	71	42.8	166	100.0
Total	117	58.5	83	41.5	200	100.0

**Table 4.** Distributional statistics on age group, barrack size and presence of *Demodex*.

	n	Age	Barrack size		
		Mean ± SD	P	Mean ± SD	P
<b>Demodex on face</b>					
No	34	21.3 ± 2.5	0.15	50.4 ± 43.9	0.63
Yes	166	21.9 ± 2.6		46.4 ± 43.7	
<b>Demodex in perinea</b>					
No	117	21.8 ± 2.3	0.56	49.0 ± 49.3	0.44
Yes	83	22.0 ± 2.8		44.5 ± 34.2	

to the results obtained in the present study.

It was concluded that, given that species of *Demodex* can be found in perinea area under conditions of collective accommodation, specimens should be taken from patients consulting with pruritus or allergic reactions in order to diagnose the parasite, and treatment protocol should be planned according to the results of the analysis.

## REFERENCES

- Abd-El-Al AM, Bayoumy AM, Abou SEA (1997). A study on *D. folliculorum* in Rosacea. *J. Egypt. Soc. Parasitol.*, 27: 183-195.
- Akdeniz S, Bahceci M, AK Tuzcu, Harman M, Alp S, Bahceci S. (2002). Is *Demodex folliculorum* larger in diabetic patients. *J. Eur. Acad. Dermatol. Venereol.*, 16: 539-541.
- Aycan ÖM, Otlu GH, Karaman Ü, Daldal N, Atambay M (2007). Prevalence of *Demodex* spp. Among various patient and age groups. *T. Parazitol. Derg.*, 31: 115-118.
- Baima B, Sticterling M (2002). Demodicidosis revisited. *Acta Derm. Venereol.* 82: 3-6.
- Baysal V, Aydemir M, Yorgancigil B, Yildirim M (1997). The role of *Demodexes* on etiology and pathogenesis of acne vulgaris. *T. Parazitol. Derg.*, 21: 265-268.
- Ding Y, Huang X (2005). Investigation of external auditory meatus secretion *Demodex folliculorum* and *Demodex brevis* infection in college students. *Lin Chuang Er Bi Yan Hou Ke Za Zhi* 19(4): 176-177.
- Dong H, Duncan LD (2006). Cytologic findings in *Demodex folliculitis*: a case report and review of the literature. *Diagn Cytopathol.*, 34: 232-234.
- Erbagci Z, Ozgoztasi O (1998). The significance of *Demodex folliculorum* density in rosacea. *Int. J. Dermatol.*, 39: 743-745.
- Forton F, Germaux MA, Brasseur T (2005). Demodicosis and rosacea: epidemiology and significance in daily dermatologic practice. *J. Am. Acad. Dermatol.*, 52: 74-87.
- Forton F, Seys B (1993). Density of *Demodex folliculorum* in rosacea: A case-control study using standardized skin-surface biopsy. *Br. J. Dermatol.*, 128: 650-659.
- Karaman U, Celik T, Calik S, Şener S, Aydin NE, Daldal UN (2008). *Demodex* spp. in Hairy Skin Biopsy Specimens. *Türkiye. Parazitol. Derg.* 32: 343-345.
- Mathieu EM, Wilson BB (2000). Mites. In. LM. Gerald, EB, John, D. Raphel ed. *Mandell, Douglas and Bennett's Principles and practice of infectious diseases.* 50 th. Ed. U.S.A. 2: 2980.
- Nutting WB (1976). Hair follicle mites (Acari: Demodicidae) of man. *Int. J. Dermatol.*, 15: 79-98.
- Saygi G, Marufi M, Köylüoğlu Z (1984). Three *Demodex folliculorum* phenomena, one detected with cellophane band. *T. Parazitol. Derg.*, 7: 137-144.
- Sener S, Karaman U, Colak C, Aydin NE, Sasmaz S, Iraz M (2009). Positivity of *Demodex* spp. in biopsy specimens of nevi. *Trop. Biomed.*, 26(1): 51-56.
- Özçelik S, Sumer Z, Değerli S, Özyazici G, Berksoy Hayta S, Akyol M, Candan F (2007). Prevalence of *Demodex folliculorum* among patients with chronic kidney failure. *T. Parazitol. Derg.*, 31: 66-66.
- Roihu T, Kariniemi AL (1998). *Demodex* Mites in Acne Rosacea. *J. Cutan Pathol.*, 25: 550-552.
- Ugras M, Miman O, Karıncaoglu Y, Atambay M (2009). The Prevalence of *Demodex folliculorum* on the Scrotum and Male Perineal Skin. *T. Parazitol. Derg.*, 33(1): 28-31.
- Wesołowska M, Baran W, Szepietowski J, Hirschberg L, Jankowski S (2005). Demodicosis in humans as a current problem in dermatology. *Wiad. Parazytol.*, 51: 253-256.