

Short Communication

Situs inversus totalis in a wistar albino rat

Bülent Salman^{1*}, Tugan Tezcaner¹, Bahadır Ege¹, Mustafa Kerem¹, Çağdaş Oto² and Tonguç Utku Yılmaz¹

¹Gazi University, Faculty of Medicine, Department of General Surgery, Ankara, Turkey.

²Ankara University, Faculty of Veterinary Medicine, Department of Anatomy, Ankara, Turkey.

Accepted 14 December, 2009

Situs inversus totalis is a rare congenital condition in which the major organs are reversed in relation to their normal position. A 12-weeks-old Wistar albino rat that had no clinical signs of disease was examined macroscopically. It was observed that the location of the heart, liver, spleen and stomach was the opposite of their normal position and that the aorta and caudal vena cava were in a reverse orientation to each other. This case report describes the anatomical features of situs inversus totalis observed in this rat.

Key words: Situs inversus, wistar albino rat.

INTRODUCTION

Situs inversus is a rare congenital malformation in which the major visceral organs are mirrored from their normal positions known as situs solitus (Shiraiwa et al., 1995). It was first described in the 18th century as the complete mirror image reversal of the thoracic and abdominal organs (Wilhelm and Holbert, 2003). This malformation can occur in both man (Afzelius, 1995; Kaya et al., 2002) and animals (Ries and König, 1988; Choi et al., 2001; Fisher et al. 2002; Neil et al., 2002; Buhl et al., 2004; Turner and Jones, 2004; Jerram et al., 2006; Tamakoshi et al., 2006) with a 1:1 ratio of males to females (Wilhelm and Holbert, 2003). In rats, the incidence of situs inversus has been reported as 0.01 - 0.2% (Shiraiwa et al., 1995). Situs inversus often does not have any adverse effects on an individual's health, and so may escape detection.

However, Kaya (2002) and Shiraiwa (1995) have reported that situs inversus can be associated with Kartegener's syndrome in humans which is an autosomal recessive disorder known as primary ciliary dyskinesia. Normally-functioning cilia determine the position of the internal organs during early embryological development, and so individuals with ciliary dyskinesia have a 50% chance of developing situs inversus (Afzelius, 1995;

Afzelius, 1998).

CASE REPORT

A Wistar albino rat was purchased from Gazi University School of Medicine, Experimental Animal Facility (Ankara, Turkey) for an independent study on pancreatic regeneration. The female rat was 12 weeks old, weighed 115 g and had no clinical abnormality. Following a midline abdominal incision during necropsy, an abnormal abdominal visceral location was observed. For this reason a median sternotomy was performed and the following macroscopic findings were observed (Figure 1).

On examination of the thoracic cavity, it was observed that the direction of the cardiac apex was reversed and the base to apex axis was towards the right of the animal (dextrocardia) (Figure 1c). Atrial location was abnormal with the caudal vena cava entering the left atrium. It was also noted that the aortic arch arose from the right ventricle and then curved to the right. Investigation of the abdominal region showed that the liver lay more to the left (Figure 1b), the spleen was located, together with the stomach, on the right side of the abdominal cavity (Figure 1a). The caecum was also reversed (Figure 1p). The common hepatic duct was located on the left side of abdomen while location of the caudal vena cava and the entrance of the portal vein to the liver were on the left side of aorta abdominalis.

*Corresponding author. E-mail: bsalman@gazi.edu.tr, dr.bsalman@yahoo.com. Tel: +90(0)312 2024196. Fax-1: +90(0)312 2124647, Fax-2: +90(0)312 2230528.

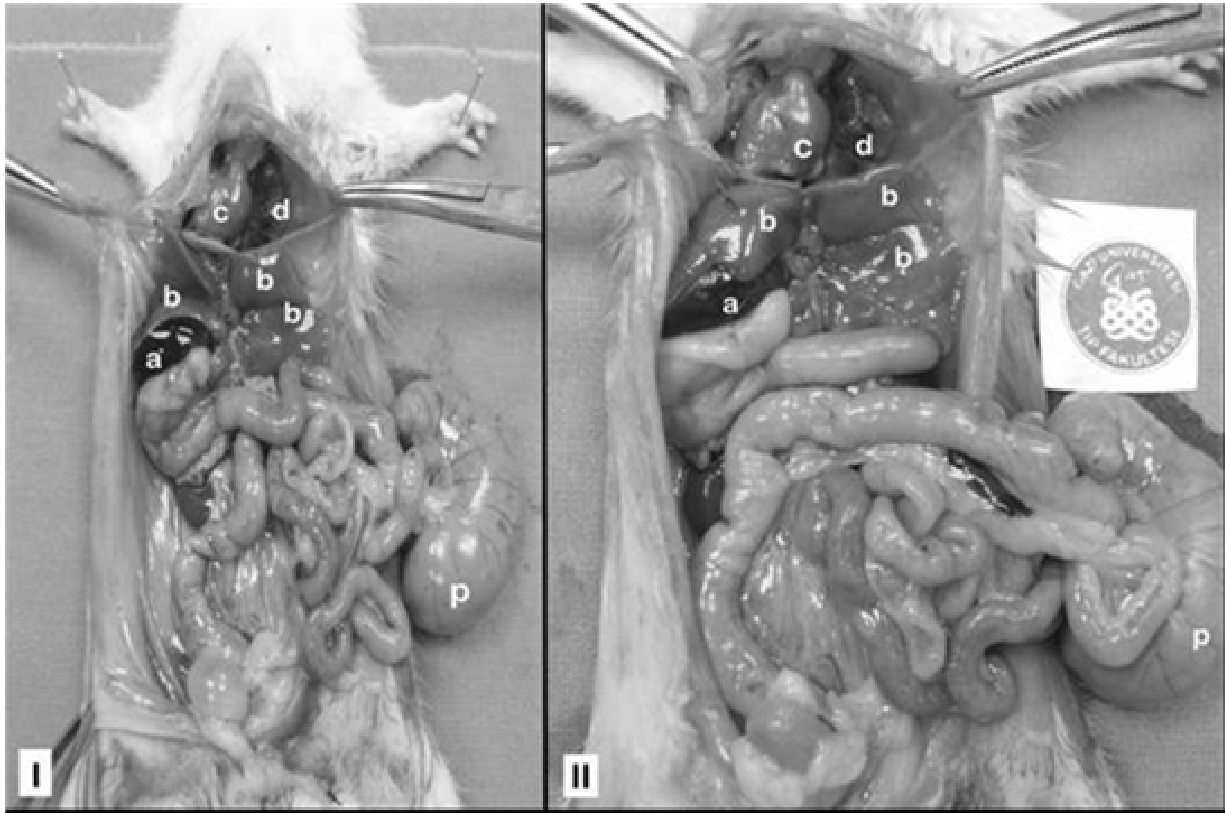


Figure 1. Situs inversus totalis found in female Wistar Albino Rat. Note transposition of the viscera. a: Spleen, b: Liver, c: Heart, d: Lung (left lobe), p: Caecum and appendix.

From these observations we conclude that this is a case of situs inversus totalis as opposed to situs inversus partialis.

REFERENCES

- Afzelius BA (1995). Situs inversus and ciliary abnormalities. What is the connection? *Int. J. Dev. Biol.* 39: 839-844.
- Afzelius BA (1998). Immotile cilia syndrome: past, present and prospects for the future. *Thorax* 53: 894-897.
- Buhl R, Koch J, Agerholm JS, Maddox-Hyttel P, Soland TM, Eriksen L (2004). Complete situs inversus in a two-year-old standard bred horse. *Vet. Rec.* 154: 600-602.
- Choi M, Hwang G, Yoo H, Yoon J, Heo J, Lee K, Chang D (2001). Radiographic diagnosis-Situs inversus of abdominal organs in a dog. *Vet. Radiol. Ultrasound.* 42: 423-425.
- Fisher KR, Wilson MS, Partlow GD (2002). Abdominal situs inversus in a Holstein calf. *Anat. Rec.* 267: 57-51.
- Jerram RM, Warman CG, Wu CT (2006). Echocardiographic and radiographic diagnosis: complete situs inversus in a Cat. *Vet. Radiol. Ultrasound.* 47: 313-315.
- Kaya A, Kaya SU, Fitöz S, Tuncali T, Gönüllü U (2002). Kartagener's syndrome. *Turk. Resp. J.* 3: 113-116.
- Neil JA, Canapp SO, Cook CR, Lattimer JC (2002). Kartagener's syndrome in a Dachshund dog. *J. Am. Anim. Hosp. Assoc.* 38: 45-49.
- Ries R, König HE (1988). Situs inversus of the lung, heart and liver. *Bull. Tierarztl. Prax.* 16: 251-252.
- Shiraiwa K, Watanabe A, Sato N, Nito M, Kobayashi Y (1995). Case report on situs inversus totalis in two sprague-dawley rats. *Exp. Anim.* 44: 341-345.
- Tamakoshi T, Itakura T, Chandra A, Uezato T, Yang Z, Xue XD, Wang B, Hackett BP, Yokoyama T, Miura N (2006). Roles of the foxj1 and inv genes in the left-right determination of internal organs in mice. *Biochem. Biophys. Res. Commun.* 339: 932-938.
- Turner SI, Jones RM (2004). Complete Situs Inversus in a horse. *Vet. Rec.* 155: 96.
- Wilhelm A, Holbert JM (2003). Situs Inversus. <http://emedicine.medscape.com/article/413679-overview>.